A 68-year-old Caucasian woman comes to the emergency department due to several hours of severe upper back pain. The patient developed the pain after experiencing a sudden jolt while driving over a pothole. She has no previous history of back pain or major trauma and has not seen a doctor in many years. The patient is retired and lives a sedentary lifestyle. She drinks a glass of wine daily and eats a healthy, balanced diet. BMI is 18.4 kg/m^2. On examination, there is point tenderness over the T10 vertebra. Neurologic examination is unremarkable. X-ray of the spine reveals a T10 compression fracture. On the graph, area C represent the normal serum concentrations of calcium and parathyroid hormone.

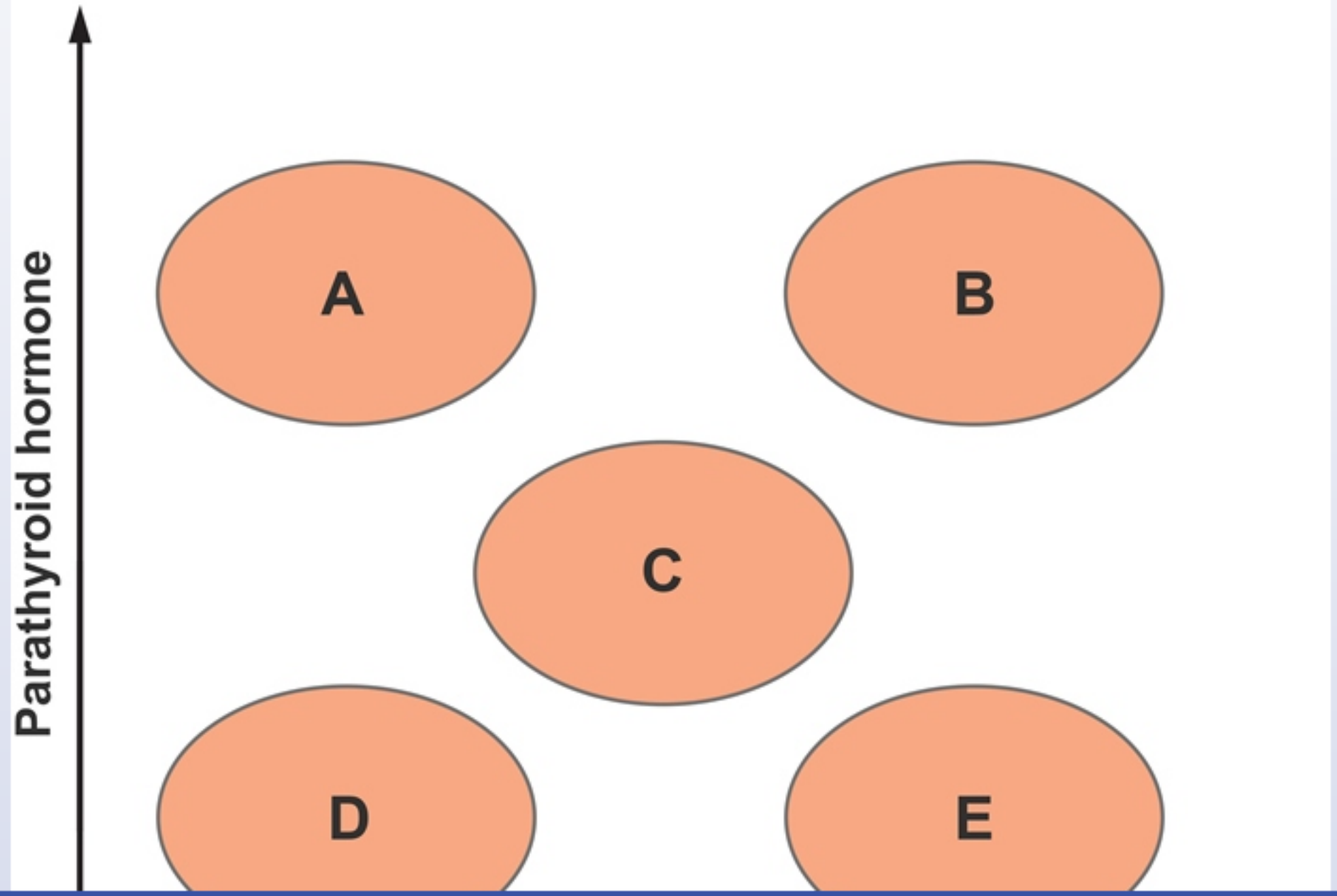

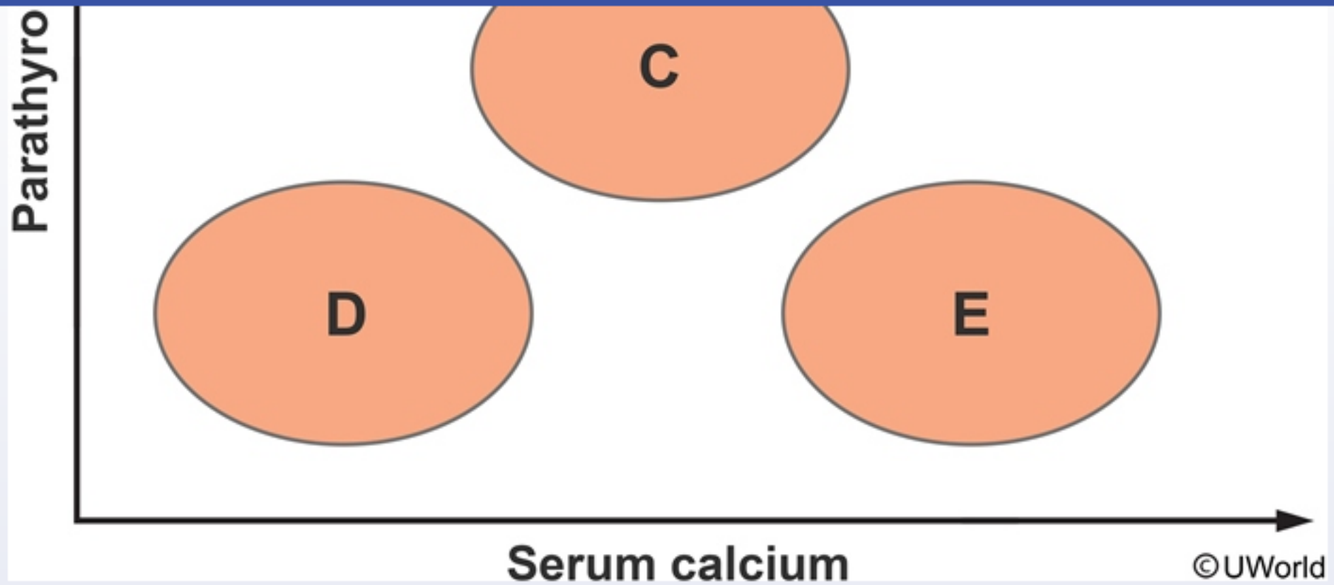

Which of the following areas most likely corresponds to this patient's current metabolic state?

- A. A
- B. B
- C. C
- D. D
- E. E

Submit

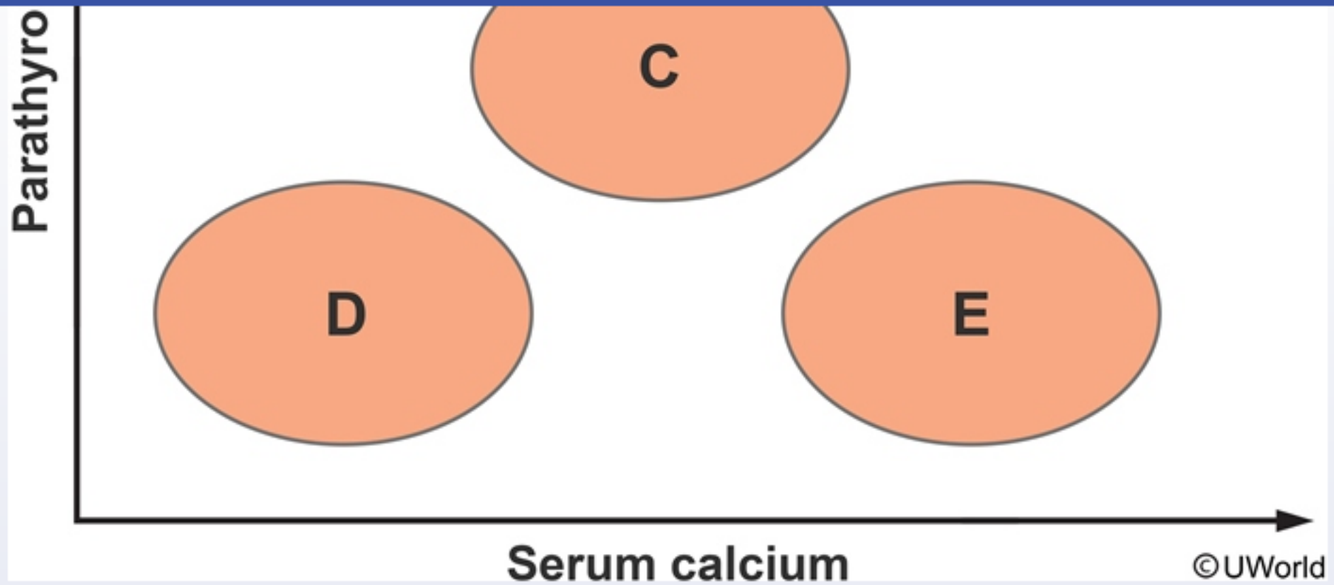

Which of the following areas most likely corresponds to this patient's current metabolic state?

- A. A (29%)
- B. B (9%)
- ✓ C. C (43%)
- D. D (7%)
- E. E (11%)

Omitted
Correct answer

43%
Answered correctly

20 secs
Time Spent

03/31/2020
Last Updated

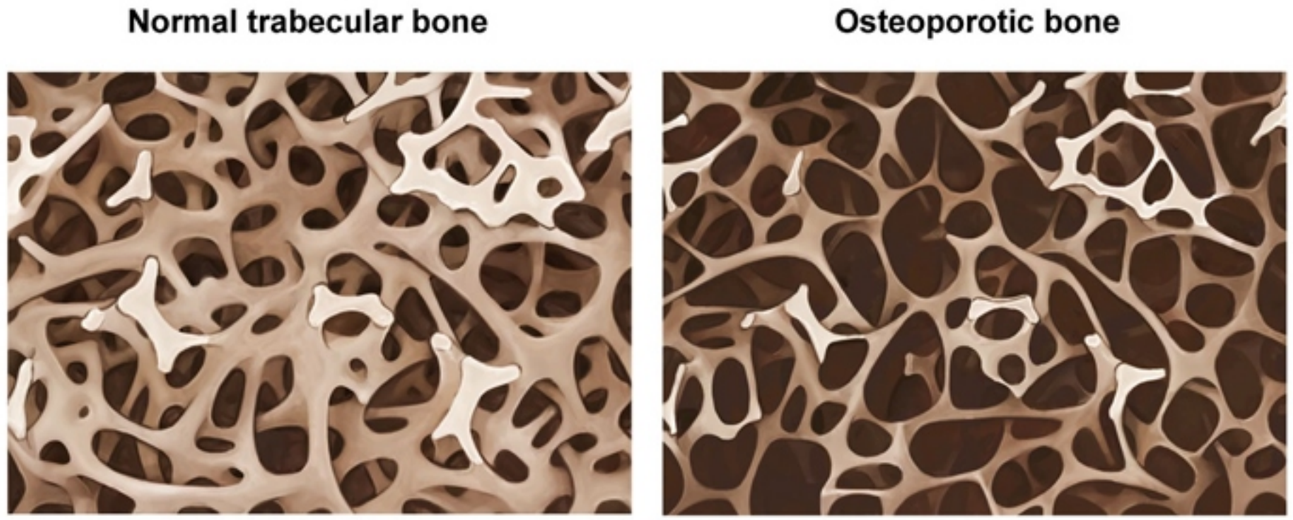

©UWorld

This patient with a thoracic compression fracture has multiple risk factors for **osteoporosis** (Caucasian ethnicity, female sex, postmenopausal status). Osteoporosis is characterized by decreased bone strength resulting from **low bone mass** and microarchitectural deterioration of bone tissue. The presence of a fragility fracture due to minimal trauma (eg, fall from a standing height) is strongly suggestive of osteoporosis.

Early postmenopausal osteoporosis primarily involves cancellous bone, which is especially important for maintaining the integrity of the vertebral column. Therefore, **vertebral fractures** are the most common manifestation of osteoporosis. With advancing age, the cortical bone (compact bone) that makes up the shafts of long bones and outer envelopes of all bones becomes more involved, leading to an increased risk of **hip fracture**.

In primary osteoporosis (ie, osteoporosis that is not due to an underlying medical disorder), serum calcium, phosphorus, and parathyroid hormone (PTH) levels are typically in the **normal** range.

(Choice A) High serum PTH with low serum calcium (area A in the diagram) is usually seen in patients with renal failure or vitamin D deficiency.

(Choices B and E) High calcium, high PTH (area B) is consistent with primary hyperparathyroidism. High calcium levels with low PTH (area E)

©UWorld

This patient with a thoracic compression fracture has multiple risk factors for **osteoporosis** (Caucasian ethnicity, female sex, postmenopausal status). Osteoporosis is characterized by decreased bone strength resulting from **low bone mass** and microarchitectural deterioration of bone tissue. The presence of a fragility fracture due to minimal trauma (eg, fall from a standing height) is strongly suggestive of osteoporosis.

Early postmenopausal osteoporosis primarily involves cancellous bone, which is especially important for maintaining the integrity of the vertebral column. Therefore, **vertebral fractures** are the most common manifestation of osteoporosis. With advancing age, the cortical bone (compact bone) that makes up the shafts of long bones and outer envelopes of all bones becomes more involved, leading to an increased risk of **hip fracture**.

In primary osteoporosis (ie, osteoporosis that is not due to an underlying medical disorder), serum calcium, phosphorus, and parathyroid hormone (PTH) levels are typically in the **normal** range.

(Choice A) High serum PTH with low serum calcium (area A in the diagram) is usually seen in patients with renal failure or vitamin D deficiency.

(Choices B and E) High calcium, high PTH (area B) is consistent with primary hyperparathyroidism. High calcium levels with low PTH (area E) would be seen in patients with PTH-independent hypercalcemia (PTH is appropriately suppressed by high calcium levels), which can occur with humoral hypercalcemia of malignancy and vitamin D toxicity.

(Choice D) In patients with hypoparathyroidism, low PTH levels cause hypocalcemia.

Educational objective:
Patients with osteoporosis have low bone mass, resulting in increased susceptibility to fragility fractures (ie, those occurring with minimal or no trauma). In primary osteoporosis (not caused by a medical disorder), serum calcium, phosphorus, and parathyroid hormone levels are typically normal.

Pathophysiology	Rheumatology/Orthopedics & Sports	Osteoporosis
Subject	System	Topic

Copyright © UWorld. All rights reserved.

©UWorld

This patient with a thoracic compression fracture has multiple risk factors for **osteoporosis** (Caucasian ethnicity, female sex, postmenopausal status). Osteoporosis is c
tissue. The presence of a

Early postmenopausal ost
column. Therefore, **verte**
bone) that makes up the s
fracture.

In primary osteoporosis (ie
(PTH) levels are typically i

(Choice A) High serum F

(Choices B and E) High
would be seen in patients
humoral hypercalcemia of

(Choice D) In patients wi

Educational objective:
Patients with osteoporosis
trauma). In primary osteo
normal.

Pathophysiology
Subject

Exhibit Display

Risk factors for osteoporotic fractures	
Nonmodifiable	**Potentially modifiable**
• Advancing age • Female sex • White, Hispanic, or Asian ethnicity • Personal or family history of fracture	• Decreased physical activity • Low body weight • Poor calcium & vitamin D intake • Excessive alcohol or tobacco use • Premature menopause • Glucocorticoid use

Add To New Card | Existing Card

Copyright © UWorld. All rights reserved.

Settings

1
2
3
4
5
6
7
8
9
10
11
12
13
14
15
16
17
18
19
20

Item 2 of 20
Question Id: 14677

Mark | Previous | Next | Full Screen | Tutorial | Lab Values | Notes | Calculator | Reverse Color | Text Zoom | Settings

A 62-year-old woman comes to the office due to a 3-month history of painful, swollen wrists and knees. She also has joint stiffness, which is worse upon wakening and limits her daily activities. Review of systems is positive for fatigue. The patient's only other medical condition is hypothyroidism for which she takes levothyroxine. She smoked a pack of cigarettes daily for 20 years and quit 15 years ago. Vitals signs are within normal limits. Physical examination shows symmetric, moderate swelling of the wrists and knees. The joints are tender and warm. Range of motion is intact but painful. Plain radiographs of the symptomatic joints show joint space narrowing and marginal erosions. Which of the following cytokines are primarily involved in the pathogenesis of this patient's joint destruction?

A. IL-1 and tumor necrosis factor-alpha

B. IL-2 and interferon gamma

C. IL-4 and IL-5

D. IL-10 and transforming growth factor-beta

E. IL-12 and IL-23

Submit

Block Time Remaining: 00:00:21
TUTOR

3 | Feedback | Suspend | End Block

A 62-year-old woman comes to the office due to a 3-month history of painful, swollen wrists and knees. She also has joint stiffness, which is worse upon wakening and limits her daily activities. Review of systems is positive for fatigue. The patient's only other medical condition is hypothyroidism for which she takes levothyroxine. She smoked a pack of cigarettes daily for 20 years and quit 15 years ago. Vitals signs are within normal limits. Physical examination shows symmetric, moderate swelling of the wrists and knees. The joints are tender and warm. Range of motion is intact but painful. Plain radiographs of the symptomatic joints show joint space narrowing and marginal erosions. Which of the following cytokines are primarily involved in the pathogenesis of this patient's joint destruction?

- ✓ A. IL-1 and tumor necrosis factor-alpha (66%)
- B. IL-2 and interferon gamma (19%)
- C. IL-4 and IL-5 (3%)
- D. IL-10 and transforming growth factor-beta (5%)
- E. IL-12 and IL-23 (4%)

Omitted
Correct answer
A

66%
Answered correctly

02 secs
Time Spent

03/24/2020
Last Updated

Explanation

This patient has chronic, **symmetric, inflammatory arthritis** associated with significant **morning stiffness** and overt **synovitis** (swelling, warmth, tenderness). In association with the radiographic findings of joint space narrowing and marginal joint erosions, this presentation is typical for **rheumatoid arthritis** (RA). RA is a progressive autoimmune disorder that has a peak incidence at age 50-75 but can occur at any age; women are affected more often than men. Systemic symptoms (eg, fatigue, fever) are common.

This patient has chronic, **symmetric, inflammatory arthritis** associated with significant **morning stiffness** and overt **synovitis** (swelling, warmth, tenderness). In association with the radiographic findings of joint space narrowing and marginal joint erosions, this presentation is typical for **rheumatoid arthritis** (RA). RA is a progressive autoimmune disorder that has a peak incidence at age 50-75 but can occur at any age; women are affected more often than men. Systemic symptoms (eg, fatigue, fever) are common.

The pathogenesis of RA involves both humoral (eg, autoantibodies against citrullinated polypeptides) and cell-mediated immunity; activation of **$CD4^+$ T cells**, especially Th1 and Th17, occurs early in the disease process. Macrophages release proinflammatory cytokines critical for the development and **progressive articular destruction** seen in RA. These include:

- **Tumor necrosis factor-alpha** (TNF-alpha) stimulates the proliferation of inflammatory cells and causes expression of inflammatory factors (eg, collagenase, prostaglandins) by synovial cells.
- **IL-1** induces synthesis of matrix metalloproteinases and enhances T-cell immune responses.

The proteases (eg, collagenase, metalloproteinase) contribute to cartilage destruction. In addition, both cytokines indirectly activate osteoclasts, resulting in bony erosions. Monoclonal antibodies that inhibit TNF-alpha (eg, adalimumab, etanercept) or IL-1 receptors (eg, anakinra) are widely used in the treatment of RA and can slow progression of the disease.

(Choice B) Activated Th1 cells produce significant quantities of IL-2 and interferon gamma, among other cytokines. Although Th1 cells and interferon gamma play a role in the pathogenesis of RA, IL-2 is less prominent. These cytokines are present in higher quantities in granulomatous diseases (eg, tuberculosis, sarcoidosis).

(Choice C) IL-4 and IL-5 are involved prominently in mast cell function and play a role in the pathogenesis of atopic disorders (eg, asthma).

(Choice D) Transforming growth factor-beta and IL-10 are antiinflammatory cytokines that downregulate lymphocyte activation and proliferation and reduce the production of proinflammatory cytokines (eg, TNF-alpha). These cytokines are likely protective of the joint destruction seen in RA.

(Choice E) IL-12 and IL-23 are produced by activated T cells and play a prominent role in the pathogenesis of psoriasis.

Educational objective:
The pathogenesis of rheumatoid arthritis involves early activation of $CD4^+$ T cells (especially Th1 and Th17 subsets) with release of cytokines

(eg, collagenase, prostaglandins) by synovial cells.

- **IL-1** induces synthesis of matrix metalloproteinases and enhances T-cell immune responses.

The proteases (eg, collagenase, metalloproteinase) contribute to cartilage destruction. In addition, both cytokines indirectly activate osteoclasts, resulting in bony erosions. Monoclonal antibodies that inhibit TNF-alpha (eg, adalimumab, etanercept) or IL-1 receptors (eg, anakinra) are widely used in the treatment of RA and can slow progression of the disease.

(Choice B) Activated Th1 cells produce significant quantities of IL-2 and interferon gamma, among other cytokines. Although Th1 cells and interferon gamma play a role in the pathogenesis of RA, IL-2 is less prominent. These cytokines are present in higher quantities in granulomatous diseases (eg, tuberculosis, sarcoidosis).

(Choice C) IL-4 and IL-5 are involved prominently in mast cell function and play a role in the pathogenesis of atopic disorders (eg, asthma).

(Choice D) Transforming growth factor-beta and IL-10 are antiinflammatory cytokines that downregulate lymphocyte activation and proliferation and reduce the production of proinflammatory cytokines (eg, TNF-alpha). These cytokines are likely protective of the joint destruction seen in RA.

(Choice E) IL-12 and IL-23 are produced by activated T cells and play a prominent role in the pathogenesis of psoriasis.

Educational objective:
The pathogenesis of rheumatoid arthritis involves early activation of $CD4^+$ T cells (especially Th1 and Th17 subsets) with release of cytokines such as tumor necrosis factor-alpha and IL-1 that cause destruction of cartilage and bone. Monoclonal antibodies that inhibit tumor necrosis factor-alpha or IL-1 receptors can slow progression of the disease.

References

- Pathogenetic insights from the treatment of rheumatoid arthritis.

Pathophysiology	Rheumatology/Orthopedics & Sports	Rheumatoid arthritis
Subject	System	Topic

Copyright © UWorld. All rights reserved.

(eg, collagenase, prostaglandins) by synovial cells.

- **IL-1** induces synthesis of matrix metalloproteinases and enhances T-cell immune responses.

The proteases (eg, collagenase, metalloproteinase) contribute to cartilage destruction. In addition, both cytokines indirectly activate osteoclasts, resulting in bony erosions. Monoclonal antibodies that inhibit TNF-alpha (eg, adalimumab, etanercept) or IL-1 receptors (eg, anakinra) are widely used in the treatment of RA and can slow progression of the disease.

(Choice B) Activated Th1 cells produce significant quantities of IL-2 and interferon gamma, among other cytokines. Although Th1 cells and interferon gamma play a role in the pathogenesis of RA, IL-2 is less prominent. These cytokines are present in higher quantities in granulomatous diseases (eg, tuberculosis, sarcoidosis).

(Choice C) IL-4 and IL-5 are involved prominently in mast cell function and play a role in the pathogenesis of atopic disorders (eg, asthma).

(Choice D) Transforming growth factor-beta and IL-10 are antiinflammatory cytokines that downregulate lymphocyte activation and proliferation and reduce the production of proinflammatory cytokines (eg, TNF-alpha). These cytokines are likely protective of the joint destruction seen in RA.

(Choice E) IL-12 and IL-23 are produced by activated T cells and play a prominent role in the pathogenesis of psoriasis.

Educational objective:
The pathogenesis of rheumatoid arthritis involves early activation of $CD4^+$ T cells (especially Th1 and Th17 subsets) with release of cytokines such as tumor necrosis factor-alpha and IL-1 that cause destruction of cartilage and bone. Monoclonal antibodies that inhibit tumor necrosis factor-alpha or IL-1 receptors can slow progression of the disease.

References

- Pathogenetic insights from the treatment of rheumatoid arthritis.

Pathophysiology	Rheumatology/Orthopedics & Sports	Rheumatoid arthritis
Subject	System	Topic

Copyright © UWorld. All rights reserved.

(eg, collagenase, prostaglandins) by synovial cells.

- **IL-1** induces synthe

The proteases (eg, collage s, resulting in bony erosions ely used in the treatment of R

(Choice B) Activated Th1 interferon gamma play a r ous diseases (eg, tuberculosis

(Choice C) IL-4 and IL-5

(Choice D) Transforming n and reduce the productior RA.

(Choice E) IL-12 and IL-2

Educational objective:
The pathogenesis of rheu such as tumor necrosis fa factor-alpha or IL-1 recept

References

- Pathogenetic insights

Pathophysiology R
Subject Sy

Copyright © UWorld. All rights reserved.

Exhibit Display

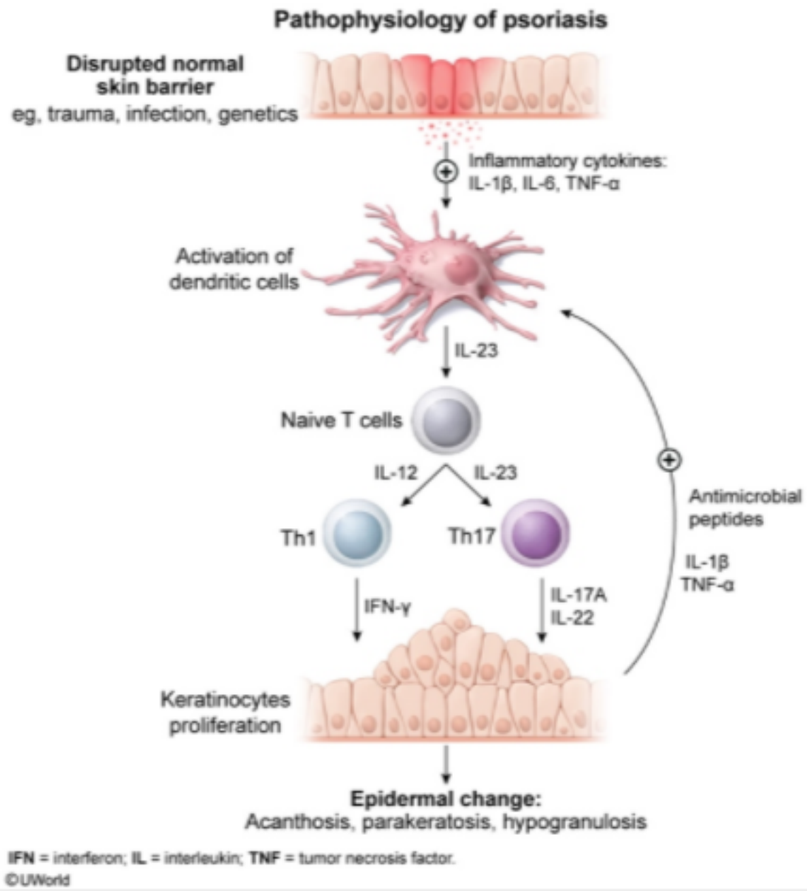

Zoom In | Zoom Out | Reset | Add To New Card | Existing Card

A 64-year-old man comes to the emergency department due to acute knee pain. He developed redness, swelling, and severe pain affecting the right knee the day before his arrival. The patient has had 3 similar episodes in the past year that resolved quickly with over-the-counter analgesics. He has a history of polycythemia vera but has been noncompliant with phlebotomy treatments. Vital signs and cardiopulmonary examinations are normal. The right knee is red and warm. There is severe pain with movement at the joint; the other joints are grossly normal. Needle aspiration of the joint is performed. Which of the following is the most likely finding on analysis of this patient's synovial fluid?

A. Clear fluid with few white blood cells

B. Gram-negative diplococci

C. Gram-positive cocci in clusters

D. Many leukocytes with no crystals or organisms

E. Needle-shaped, negatively birefringent crystals

F. Numerous red blood cells

G. Rhomboid-shaped, positively birefringent crystals

Submit

A 64-year-old man comes to the emergency department due to acute knee pain. He developed redness, swelling, and severe pain affecting the right knee the day before his arrival. The patient has had 3 similar episodes in the past year that resolved quickly with over-the-counter analgesics. He has a history of polycythemia vera but has been noncompliant with phlebotomy treatments. Vital signs and cardiopulmonary examinations are normal. The right knee is red and warm. There is severe pain with movement at the joint; the other joints are grossly normal. Needle aspiration of the joint is performed. Which of the following is the most likely finding on analysis of this patient's synovial fluid?

A. Clear fluid with few white blood cells (1%)

B. Gram-negative diplococci (1%)

C. Gram-positive cocci in clusters (3%)

D. Many leukocytes with no crystals or organisms (6%)

✓ E. Needle-shaped, negatively birefringent crystals (56%)

F. Numerous red blood cells (10%)

G. Rhomboid-shaped, positively birefringent crystals (18%)

Omitted
Correct answer
E

56%
Answered correctly

02 secs
Time Spent

01/19/2020
Last Updated

Explanation

Causes of gout

Causes of gout	
Increased urate production	• **Primary gout** (idiopathic) • Myeloproliferative/lymphoproliferative disorders • Tumor lysis syndrome • Hypoxanthine guanine phosphoribosyl transferase deficiency
Decreased urate clearance	• Chronic kidney disease • Thiazide/loop diuretics

©UWorld

This patient, with recurrent acute monoarthritis and history of a myeloproliferative disorder, has typical features of **gout**. Gout occurs when there is an increased **uric acid** concentration in serum and synovial fluid, leading to monosodium urate crystal formation and deposition in synovium and cartilage. Gout is most common in joints where cooler temperatures favor crystal formation, especially in the distal lower extremity (eg, **first metatarsophalangeal joint**, ankle, knee). Uptake of urate crystals by neutrophils leads to free radical release, cytokine production, and joint inflammation. The hyperuricemia that predisposes to gout can be idiopathic (primary gout) or due to increased urate production (eg, myeloproliferative disorders) or decreased urate clearance by the kidneys.

Gouty arthritis presents with acute onset of severe joint pain, warmth, erythema, and swelling. The diagnosis is established by synovial fluid analysis, which shows increased white blood cells. Monosodium urate crystals are seen under polarized light microscopy and may be present both intra- and extracellularly. They are characteristically **needle-shaped** and **negatively birefringent** (when the crystals are aligned parallel to the slow ray of the compensator, they appear yellow; when aligned perpendicular, they appear blue).

(Choice A) Osteoarthritis causes chronic, progressive arthritis in the distal hands and weight-bearing joints. Synovial fluid analysis shows normal to minimal inflammatory findings.

Gouty arthritis presents with acute onset of severe joint pain, warmth, erythema, and swelling. The diagnosis is established by synovial fluid analysis, which shows increased white blood cells. Monosodium urate crystals are seen under polarized light microscopy and may be present both intra- and extracellularly. They are characteristically **needle-shaped** and **negatively birefringent** (when the crystals are aligned parallel to the slow ray of the compensator, they appear yellow; when aligned perpendicular, they appear blue).

(Choice A) Osteoarthritis causes chronic, progressive arthritis in the distal hands and weight-bearing joints. Synovial fluid analysis shows normal to minimal inflammatory findings.

(Choices B and C) Gonococcal arthritis presents with fever, skin lesions, and inflammatory mono- or oligoarthritis. Staphylococcal septic arthritis causes a fulminant monoarthritis, usually with fever. Recurrent episodes are more characteristic of gout.

(Choice D) Rheumatoid arthritis causes a chronic polyarthritis, typically involving the metacarpophalangeal joints of the hands. Synovial fluid will show a sterile inflammatory effusion.

(Choice F) Nontraumatic hemarthrosis is most commonly seen in patients taking anticoagulants (eg, warfarin) or with bleeding disorders (eg, hemophilia).

(Choice G) Crystal arthritis due to calcium pyrophosphate deposition (pseudogout) most commonly affects the knee and is often similar to gout. However, it is less common and not associated with myeloproliferative disorders.

Educational objective:
Gout results from the deposition of monosodium urate crystals in the joints and soft tissues. Under polarized light, urate crystals appear needle-shaped and negatively birefringent. Conditions that increase uric acid production or decrease uric acid clearance can increase the risk of gout.

References

- Hyperuricemia, gout, and related comorbidities: cause and effect on a two-way street.

Pathophysiology	Rheumatology/Orthopedics & Sports	Gout
Subject	System	Topic

Exhibit Display



Zoom In | Zoom Out | Reset | Add To New Card | Existing Card

Settings

1
2
3
4
5
6
7
8
9
10
11
12
13
14
15
16
17
18
19
20

Item 4 of 20
Question Id: 15564

Mark | Previous | Next | Full Screen | Tutorial | Lab Values | Notes | Calculator | Reverse Color | Text Zoom | Settings

A 33-year-old woman comes to the office due to swelling affecting her extremities. Over the last 12 months her fingers, arms, and legs have become progressively swollen and somewhat itchy. Physical examination shows diffuse skin thickening extending proximally to the arms, thighs, and trunk. A skin biopsy is performed. Histologic sections show expansion of the dermal layer with atrophy of the intradermal adipose tissue and dermal appendages. High-power images of the dermis demonstrate extensive deposition of dense, eosinophilic connective tissue. This patient is most at risk for which of the following conditions?

A. Atlantoaxial subluxation
B. Glomerulonephritis
C. Interstitial lung disease
D. Non-Hodgkin lymphoma
E. Ulcerative colitis

Submit

Block Time Remaining: 00:00:25
TUTOR

0 | Feedback | Suspend | End Block

A 33-year-old woman comes to the office due to swelling affecting her extremities. Over the last 12 months her fingers, arms, and legs have become progressively swollen and somewhat itchy. Physical examination shows diffuse skin thickening extending proximally to the arms, thighs, and trunk. A skin biopsy is performed. Histologic sections show expansion of the dermal layer with atrophy of the intradermal adipose tissue and dermal appendages. High-power images of the dermis demonstrate extensive deposition of dense, eosinophilic connective tissue. This patient is most at risk for which of the following conditions?

- A. Atlantoaxial subluxation (5%)
- B. Glomerulonephritis (20%)
- ✓ C. Interstitial lung disease (56%)
- D. Non-Hodgkin lymphoma (6%)
- E. Ulcerative colitis (10%)

Omitted
Correct answer
C

56%
Answered correctly

02 secs
Time Spent

06/23/2020
Last Updated

Explanation

Systemic sclerosis		
	Limited cutaneous	Diffuse cutaneous
Manifestations	• Distal sclerosis (most prominent in the fingers)	• Proximal sclerosis (involves the trunk & proximal

Systemic sclerosis		
	Limited cutaneous	Diffuse cutaneous
Manifestations	• Distal sclerosis (most prominent in the fingers) • CREST syndrome	• Proximal sclerosis (involves the trunk & proximal extremities)
Serology	• Anticentromere	• Anti-SCL-70
Complications	• Pulmonary hypertension	• Interstitial lung disease • Scleroderma renal crisis

Anti-SCL-70 = anti-topoisomerase I; **CREST** = Calcinosis cutis, Raynaud phenomenon, Esophageal dysmotility, Sclerodactyly, Telangiectasia.

This patient has diffuse skin thickening consistent with **systemic sclerosis** (SS), an autoimmune disease characterized by widespread **fibrosis** of multiple organ systems. Early symptoms often include swelling of the fingers and mild pruritus. A characteristic skin biopsy finding is **dermal layer expansion** due to diffuse deposition of collagen (eosinophilic connective tissue), resulting in **atrophy** of the **intradermal adipose** tissue and **dermal appendages** (ie, hair follicles, glands).

Up to 80% of patients with SS develop pulmonary complications, with the incidence depending on the SS subtype:

- **Interstitial lung disease** is the most common pulmonary complication of **diffuse cutaneous SS** (ie, skin involvement extends proximal to the wrist and may include the trunk).
- **Pulmonary hypertension** is the most common pulmonary complication of limited cutaneous SS (ie, skin involvement is mainly in the hands and/or face), which is often associated with CREST syndrome.

(Choice A) Atlantoaxial subluxation is a feared complication of rheumatoid arthritis, as significant neck extension (eg, during intubation) can result in dislocation and spinal cord injury. Rheumatoid arthritis typically presents with pain and swelling of the small joints of the hands and wrists; histology reveals synovial hyperplasia.

(Choice B) SS is associated with scleroderma renal crisis; however, this occurs due to renal vascular injury, not glomerulonephritis. Scleroderma

Up to 80% of patients with SS develop pulmonary complications, with the incidence depending on the SS subtype:

- **Interstitial lung disease** is the most common pulmonary complication of **diffuse cutaneous SS** (ie, skin involvement extends proximal to the wrist and may include the trunk).
- **Pulmonary hypertension** is the most common pulmonary complication of limited cutaneous SS (ie, skin involvement is mainly in the hands and/or face), which is often associated with CREST syndrome.

(Choice A) Atlantoaxial subluxation is a feared complication of rheumatoid arthritis, as significant neck extension (eg, during intubation) can result in dislocation and spinal cord injury. Rheumatoid arthritis typically presents with pain and swelling of the small joints of the hands and wrists; histology reveals synovial hyperplasia.

(Choice B) SS is associated with scleroderma renal crisis; however, this occurs due to renal vascular injury, not glomerulonephritis. Scleroderma renal crisis often presents as hypertensive emergency with signs of end-organ dysfunction; casts (which are typical in glomerulonephritis) are characteristically absent.

(Choice D) Non-Hodgkin lymphoma is a potential complication of Sjögren syndrome, which typically presents with dry mouth and eyes. Labial salivary gland biopsy demonstrates extensive lymphoid infiltrate with atrophy of the acinar gland.

(Choice E) Ulcerative colitis is often associated with ankylosing spondylitis. Although dactylitis (ie, sausage fingers) can occur with this condition, skin thickening and collagen deposition would be unexpected.

Educational objective:
Systemic sclerosis (SS) is an autoimmune disease characterized by the widespread fibrosis of multiple organ systems. Histology demonstrates expansion of the dermal layer with diffuse collagen deposition and atrophy of the intradermal adipose tissue and dermal appendages. Pulmonary complications are common (eg, interstitial lung disease, pulmonary hypertension).

Pathophysiology	Rheumatology/Orthopedics & Sports	Systemic sclerosis
Subject	System	Topic

Copyright © UWorld. All rights reserved.

Up to 90% of patients with SS develop pulmonary complications, with the incidence depending on the SS subtype:

Exhibit Display

CREST syndrome characteristics
Calcinosis
Raynaud phenomenon
Esophageal dysmotility
Sclerodactyly
Telangiectasias

©UWorld

Zoom In
Zoom Out
Reset
Add To Flash Card

Copyright © UWorld. All rights reserved.

Up to 90% of patients with SS develop pulmonary complications, with the incidence depending on the SS subtype:

Exhibit Display

Sjogren syndrome

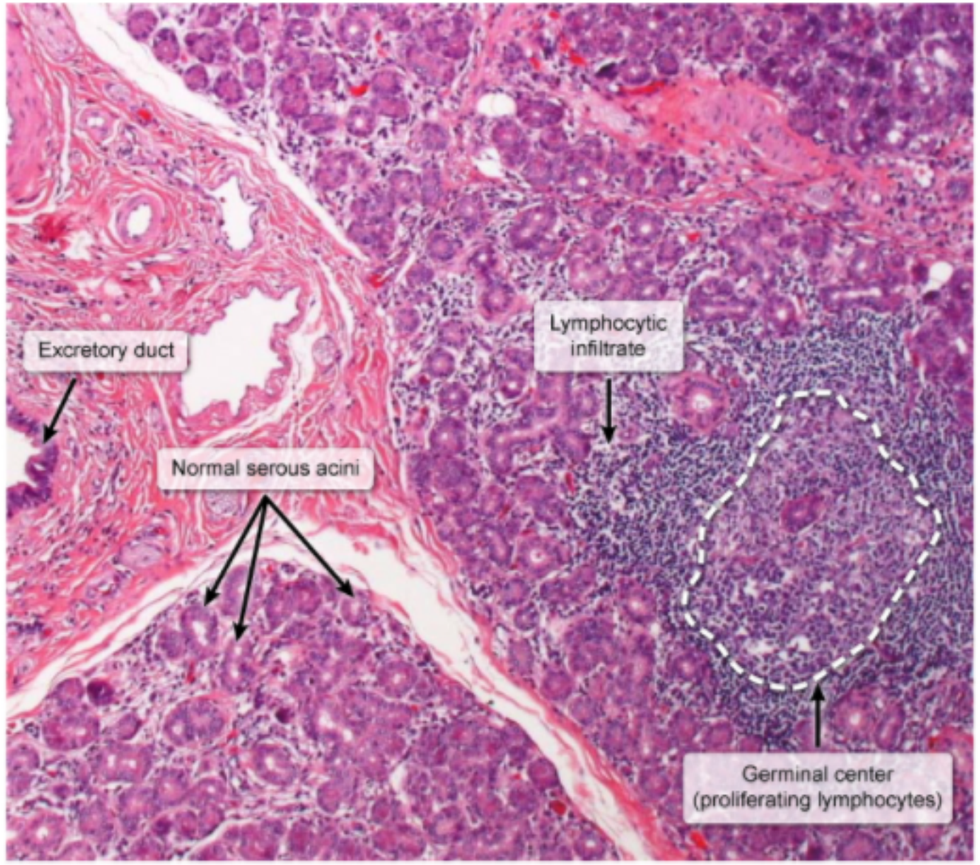

©UWorld

Zoom In | Zoom Out | Reset | Add To Flash Card

Copyright © UWorld. All rights reserved.

Settings

1
2
3
4
5
6
7
8
9
10
11
12
13
14
15
16
17
18
19
20

Item 5 of 20
Question Id: 748

Mark | Previous | Next | Full Screen | Tutorial | Lab Values | Notes | Calculator | Reverse Color | Text Zoom | Settings

A 43-year-old man comes to the office with muscle weakness. His symptoms began 6 weeks ago and are worst in the hips and shoulders. The weakness has had a progressive course so that he is now having difficulty rising from chairs and combing his hair. The patient has had to reduce his regular exercise regimen due to weakness and has requested a modified work schedule for his job as a building maintenance manager. He has no history of spinal injury and no neck pain. Past medical history is insignificant, and the patient takes no medications. Muscle biopsy reveals major histocompatibility complex class I molecule overexpression on the sarcolemma with $CD8^+$ lymphocyte infiltration. Which of the following is the most likely cause of this patient's condition?

A. Diffuse systemic sclerosis
B. Eaton-Lambert syndrome
C. Myasthenia gravis
D. Polyarteritis nodosa
E. Polymyalgia rheumatica
F. Polymyositis

Submit

Block Time Remaining: 00:00:27
TUTOR

3 | Feedback | Suspend | End Block

A 43-year-old man comes to the office with muscle weakness. His symptoms began 6 weeks ago and are worst in the hips and shoulders. The weakness has had a progressive course so that he is now having difficulty rising from chairs and combing his hair. The patient has had to reduce his regular exercise regimen due to weakness and has requested a modified work schedule for his job as a building maintenance manager. He has no history of spinal injury and no neck pain. Past medical history is insignificant, and the patient takes no medications. Muscle biopsy reveals major histocompatibility complex class I molecule overexpression on the sarcolemma with $CD8^+$ lymphocyte infiltration. Which of the following is the most likely cause of this patient's condition?

- A. Diffuse systemic sclerosis (1%)
- B. Eaton-Lambert syndrome (7%)
- C. Myasthenia gravis (4%)
- D. Polyarteritis nodosa (0%)
- E. Polymyalgia rheumatica (10%)
- ✓ F. Polymyositis (75%)

Omitted
Correct answer
F

75%
Answered correctly

03 secs
Time Spent

05/04/2020
Last Updated

Explanation

Polymyositis

Polymyositis	
Clinical presentation	• Symmetrical proximal **muscle weakness** • Increasing difficulty climbing stairs, getting up from a chair, carrying heavy objects
Pathologic features	• **Elevated muscle enzymes** (CK, aldolase) • Autoantibodies (ANA, anti–Jo-1) • **Biopsy**: Endomysial mononuclear infiltrate, patchy necrosis
Associated complications	• Interstitial lung disease • Myocarditis

ANA = antinuclear antibodies; **CK** = creatine kinase.

This patient, a middle-aged man with progressive, symmetric **proximal muscle weakness**, has typical symptoms of **polymyositis**. The weakness may be painless or associated with diffuse myalgias. Muscle enzyme levels (eg, creatine kinase) are invariably elevated, and autoantibodies (eg, antinuclear antibodies, anti-Jo-1 antibodies) are present in most cases. Polymyositis is similar to dermatomyositis, although it lacks the typical skin findings; both may occur independently or as a paraneoplastic manifestation of an underlying malignancy.

Polymyositis is an inflammatory myopathy triggered by unknown, possibly viral, antigens. It likely represents a cell-mediated immune response against myocytes. Increased expression of **major histocompatibility complex class I** antigens on the sarcolemma has been demonstrated and likely leads to presentation of autoantigens to **$CD8^+$ cytotoxic cells** that subsequently initiate myocyte destruction. Muscle biopsy in polymyositis reveals inflammation, patchy necrosis, and regeneration and fibrosis of muscle fibers. Infiltration of the endomysium by macrophages and $CD8^+$ lymphocytes is typically seen.

(Choice A) Joint involvement in systemic sclerosis may cause arthralgias and contractures, but muscle weakness is not seen.

(Choices B and C) Myasthenia gravis is caused by anti-acetylcholine receptor autoantibodies and is characterized by episodic weakness that

This patient, a middle-aged man with progressive, symmetric **proximal muscle weakness**, has typical symptoms of **polymyositis**. The weakness may be painless or associated with diffuse myalgias. Muscle enzyme levels (eg, creatine kinase) are invariably elevated, and autoantibodies (eg, antinuclear antibodies, anti-Jo-1 antibodies) are present in most cases. Polymyositis is similar to dermatomyositis, although it lacks the typical skin findings; both may occur independently or as a paraneoplastic manifestation of an underlying malignancy.

Polymyositis is an inflammatory myopathy triggered by unknown, possibly viral, antigens. It likely represents a cell-mediated immune response against myocytes. Increased expression of **major histocompatibility complex class I** antigens on the sarcolemma has been demonstrated and likely leads to presentation of autoantigens to **$CD8^+$ cytotoxic cells** that subsequently initiate myocyte destruction. Muscle biopsy in polymyositis reveals inflammation, patchy necrosis, and regeneration and fibrosis of muscle fibers. Infiltration of the endomysium by macrophages and $CD8^+$ lymphocytes is typically seen.

(Choice A) Joint involvement in systemic sclerosis may cause arthralgias and contractures, but muscle weakness is not seen.

(Choices B and C) Myasthenia gravis is caused by anti-acetylcholine receptor autoantibodies and is characterized by episodic weakness that initially affects the ocular/bulbar musculature. The Eaton-Lambert myasthenic syndrome is a paraneoplastic condition causing fatigable weakness in the extremities; it is caused by autoantibodies to presynaptic calcium channels. Light microscopy of muscle biopsy specimens is normal in these conditions.

(Choice D) Polyarteritis nodosa is an uncommon systemic vasculitis that presents with intermittent episodes of abdominal pain, peripheral neuropathy, renal insufficiency, and severe hypertension. Biopsy is characterized by transmural inflammation of the arterial wall with fibrinoid necrosis.

(Choice E) Polymyalgia rheumatica (PMR) causes myalgias of the shoulder and pelvic girdle muscles, often with systemic symptoms (eg, fever, weight loss). Weakness is not typical, and PMR occurs almost exclusively in patients age >50.

Educational objective:
Polymyositis causes symmetric proximal muscle weakness. Muscle biopsy reveals inflammation, necrosis, and regeneration of muscle fibers. Over-expression of major histocompatibility complex class I proteins on the sarcolemma leads to infiltration with $CD8^+$ T lymphocytes and myocyte damage.

Settings

1
2
3
4
5
6
7
8
9
10
11
12
13
14
15
16
17
18
19
20

Item 5 of 20
Question Id: 748

Mark | Previous | Next | Full Screen | Tutorial | Lab Values | Notes | Calculator | Reverse Color | Text Zoom | Settings

Exhibit Display

Zoom In | Zoom Out | Reset | Add To New Card | Existing Card

Block Time Remaining: 00:00:29
TUTOR

3 | Feedback | Suspend | End Block

likely leads to presentation of autoantigens to **CD8⁺ cytotoxic cells** that subsequently initiate myocyte destruction. Muscle biopsy in polymyositis reveals inflammation, patchy necrosis, and regeneration and fibrosis of muscle fibers. Infiltration of the endomysium by macrophages and CD8⁺ lymphocytes is typically seen.

(Choice A) Joint involvement in systemic sclerosis may cause arthralgias and contractures, but muscle weakness is not seen.

(Choices B and C) Myasthenia gravis is caused by anti-acetylcholine receptor autoantibodies and is characterized by episodic weakness that initially affects the ocular/bulbar musculature. The Eaton-Lambert myasthenic syndrome is a paraneoplastic condition causing fatigable weakness in the extremities; it is caused by autoantibodies to presynaptic calcium channels. Light microscopy of muscle biopsy specimens is normal in these conditions.

(Choice D) Polyarteritis nodosa is an uncommon systemic vasculitis that presents with intermittent episodes of abdominal pain, peripheral neuropathy, renal insufficiency, and severe hypertension. Biopsy is characterized by transmural inflammation of the arterial wall with fibrinoid necrosis.

(Choice E) Polymyalgia rheumatica (PMR) causes myalgias of the shoulder and pelvic girdle muscles, often with systemic symptoms (eg, fever, weight loss). Weakness is not typical, and PMR occurs almost exclusively in patients age >50.

Educational objective:
Polymyositis causes symmetric proximal muscle weakness. Muscle biopsy reveals inflammation, necrosis, and regeneration of muscle fibers. Over-expression of major histocompatibility complex class I proteins on the sarcolemma leads to infiltration with CD8⁺ T lymphocytes and myocyte damage.

References

- Mechanisms of disease: signaling pathways and immunobiology of inflammatory myopathies.

Pathophysiology	Rheumatology/Orthopedics & Sports	Polymyositis and dermatomyositis
Subject	System	Topic

Copyright © UWorld. All rights reserved.

Settings

1
2
3
4
5
6
7
8
9
10
11
12
13
14
15
16
17
18
19
20

Item 6 of 20
Question Id: 1600

Mark | Previous | Next | Full Screen | Tutorial | Lab Values | Notes | Calculator | Reverse Color | Text Zoom | Settings

A 35-year-old man comes to the clinic with acute right knee pain and swelling. His symptoms have been present for a week and have moderately worsened over this period. The patient is able to bear weight but has significant pain when climbing stairs or walking for extended distances. He attempted treatment with ibuprofen, which provided prompt but only temporary relief. Past medical history is unremarkable, though the patient was seen by his primary care provider for a diarrheal illness 2 weeks before onset of the current symptoms. Examination shows a moderate-sized effusion at the right knee. Cultures of a joint aspirate reveal no bacteria. Which of the following is most likely associated with this patient's joint symptoms?

A. C1 inhibitor deficiency

B. High titers of antistreptolysin O antibodies

C. Histocompatibility antigen HLA-B27

D. Positive serum antinuclear antibodies

E. Positive serum rheumatoid factor

Submit

Block Time Remaining: 00:00:29
TUTOR

5 | Feedback | Suspend | End Block

A 35-year-old man comes to the clinic with acute right knee pain and swelling. His symptoms have been present for a week and have moderately worsened over this period. The patient is able to bear weight but has significant pain when climbing stairs or walking for extended distances. He attempted treatment with ibuprofen, which provided prompt but only temporary relief. Past medical history is unremarkable, though the patient was seen by his primary care provider for a diarrheal illness 2 weeks before onset of the current symptoms. Examination shows a moderate-sized effusion at the right knee. Cultures of a joint aspirate reveal no bacteria. Which of the following is most likely associated with this patient's joint symptoms?

- A. C1 inhibitor deficiency (5%)
- B. High titers of antistreptolysin O antibodies (11%)
- ✓ C. Histocompatibility antigen HLA-B27 (71%)
- D. Positive serum antinuclear antibodies (6%)
- E. Positive serum rheumatoid factor (5%)

Omitted
Correct answer
C

71%
Answered correctly

01 sec
Time Spent

01/19/2020
Last Updated

Explanation

Reactive arthritis	
	• **Genitourinary infection:** *Chlamydia trachomatis*

Reactive arthritis	
Preceding infection	• **Genitourinary infection:** *Chlamydia trachomatis* • **Enteritis:** *Salmonella, Shigella, Yersinia, Campylobacter, Clostridioides* (formerly *Clostridium*) *difficile*
Musculoskeletal	• Asymmetric oligo**arthritis** • Enthesitis • Dactylitis
Extraarticular symptoms	• Ocular: **conjunctivitis**, anterior uveitis • Genital: **urethritis**, cervicitis, prostatitis • Dermal: keratoderma blennorrhagicum, circinate balanitis • Oral ulcers

This patient, a young man with acute lower extremity arthritis and a sterile joint effusion following a gastrointestinal infection, has typical symptoms of **reactive arthritis**. Reactive arthritis is a spondyloarthropathy that preferentially affects **HLA-B27-positive** individuals. It typically presents as an asymmetric arthritis of the large joints. Common associated symptoms include conjunctivitis, urethritis, and keratoderma blennorrhagicum.

Reactive arthritis is most common following infections with *Campylobacter, Shigella, Salmonella, Yersinia, Chlamydia*, or *Bartonella*. The clinical manifestations are caused by **immune complexes** involving bacterial antigens. However, it does not represent disseminated infection, and joint aspirates are sterile (ie, it is a 'reactive' not infectious arthritis).

(Choice A) C1 inhibitor deficiency is associated with hereditary angioedema. C1 inhibitor degrades C1 and prevents excessive complement activation and inflammation.

(Choice B) High titers of antistreptolysin O antibody are seen in nonpurulent complications of group A streptococcal infections, such as rheumatic fever and glomerulonephritis.

(Choices D and E) Antinuclear antibody and rheumatoid factor are nonspecific markers of autoimmune disease, primarily systemic lupus

This patient, a young man with acute lower extremity arthritis and a sterile joint effusion following a gastrointestinal infection, has typical symptoms of **reactive arthritis**. Reactive arthritis is a spondyloarthropathy that preferentially affects **HLA-B27-positive** individuals. It typically presents as an asymmetric arthritis of the large joints. Common associated symptoms include conjunctivitis, urethritis, and keratoderma blennorrhagicum.

Reactive arthritis is most common following infections with *Campylobacter, Shigella, Salmonella, Yersinia, Chlamydia*, or *Bartonella*. The clinical manifestations are caused by **immune complexes** involving bacterial antigens. However, it does not represent disseminated infection, and joint aspirates are sterile (ie, it is a 'reactive' not infectious arthritis).

(Choice A) C1 inhibitor deficiency is associated with hereditary angioedema. C1 inhibitor degrades C1 and prevents excessive complement activation and inflammation.

(Choice B) High titers of antistreptolysin O antibody are seen in nonpurulent complications of group A streptococcal infections, such as rheumatic fever and glomerulonephritis.

(Choices D and E) Antinuclear antibody and rheumatoid factor are nonspecific markers of autoimmune disease, primarily systemic lupus erythematosus and rheumatoid arthritis, respectively. These conditions are less common in men, do not usually present with acute monoarthritis, and are not associated with recent diarrheal illness.

Educational objective:
Reactive arthritis is a spondyloarthropathy associated with HLA-B27 that can occur following infection with *Chlamydia, Campylobacter, Salmonella, Shigella*, or *Yersinia*. It presents with sterile arthritis due to deposition of immune complexes.

References

- Diagnosis and classification of reactive arthritis.

Pathophysiology	Rheumatology/Orthopedics & Sports	Reactive arthritis
Subject	System	Topic

Copyright © UWorld. All rights reserved.

Settings

1
2
3
4
5
6
7
8
9
10
11
12
13
14
15
16
17
18
19
20

Item 6 of 20
Question Id: 1600

Mark | Previous | Next | Full Screen | Tutorial | Lab Values | Notes | Calculator | Reverse Color | Text Zoom | Settings

Exhibit Display

Zoom In | Zoom Out | Reset | Add To New Card | Existing Card

Block Time Remaining: 00:00:30
TUTOR

5 | Feedback | Suspend | End Block

A 65-year-old man comes to the emergency department with a 3-day history of headaches localized to the right temporal region. The headaches are accompanied by intermittent blurring of vision in both eyes. He has also felt fatigued for the past week, with stiffness in his shoulders and hips. On examination, temperature is 37.5 C (99.5 F). There is tenderness on palpation of the right temporal region with enlargement of the underlying artery, as shown in the exhibit. Funduscopic examination reveals edematous optic discs in both eyes. The patient has limited active abduction of the shoulder joints bilaterally. Laboratory studies show an erythrocyte sedimentation rate of 115 mm/hr. Which of the following is the most important mediator of this patient's current condition?

A. Antibodies to myeloperoxidase

B. Antibodies to proteinase-3

C. B cell-activating factor

D. Interleukin-6

E. Matrix metalloproteinase

Submit

Settings

1
2
3
4
5
6
7
8
9
10
11
12
13
14
15
16
17
18
19
20

Item 7 of 20
Question Id: 11770

Mark | Previous | Next | Full Screen | Tutorial | Lab Values | Notes | Calculator | Reverse Color | Text Zoom | Settings

Exhibit Display

Zoom In | Zoom Out | Reset | Add To New Card | Existing Card

Block Time Remaining: 00:00:34
TUTOR

4 | Feedback | Suspend | End Block

A 65-year-old man comes to the emergency department with a 3-day history of headaches localized to the right temporal region. The headaches are accompanied by intermittent blurring of vision in both eyes. He has also felt fatigued for the past week, with stiffness in his shoulders and hips. On examination, temperature is 37.5 C (99.5 F). There is tenderness on palpation of the right temporal region with enlargement of the underlying artery, as shown in the exhibit. Funduscopic examination reveals edematous optic discs in both eyes. The patient has limited active abduction of the shoulder joints bilaterally. Laboratory studies show an erythrocyte sedimentation rate of 115 mm/hr. Which of the following is the most important mediator of this patient's current condition?

A. Antibodies to myeloperoxidase (12%)

B. Antibodies to proteinase-3 (12%)

C. B cell-activating factor (5%)

✓ D. Interleukin-6 (54%)

E. Matrix metalloproteinase (16%)

Omitted
Correct answer
D

54%
Answered correctly

07 secs
Time Spent

05/05/2020
Last Updated

Explanation

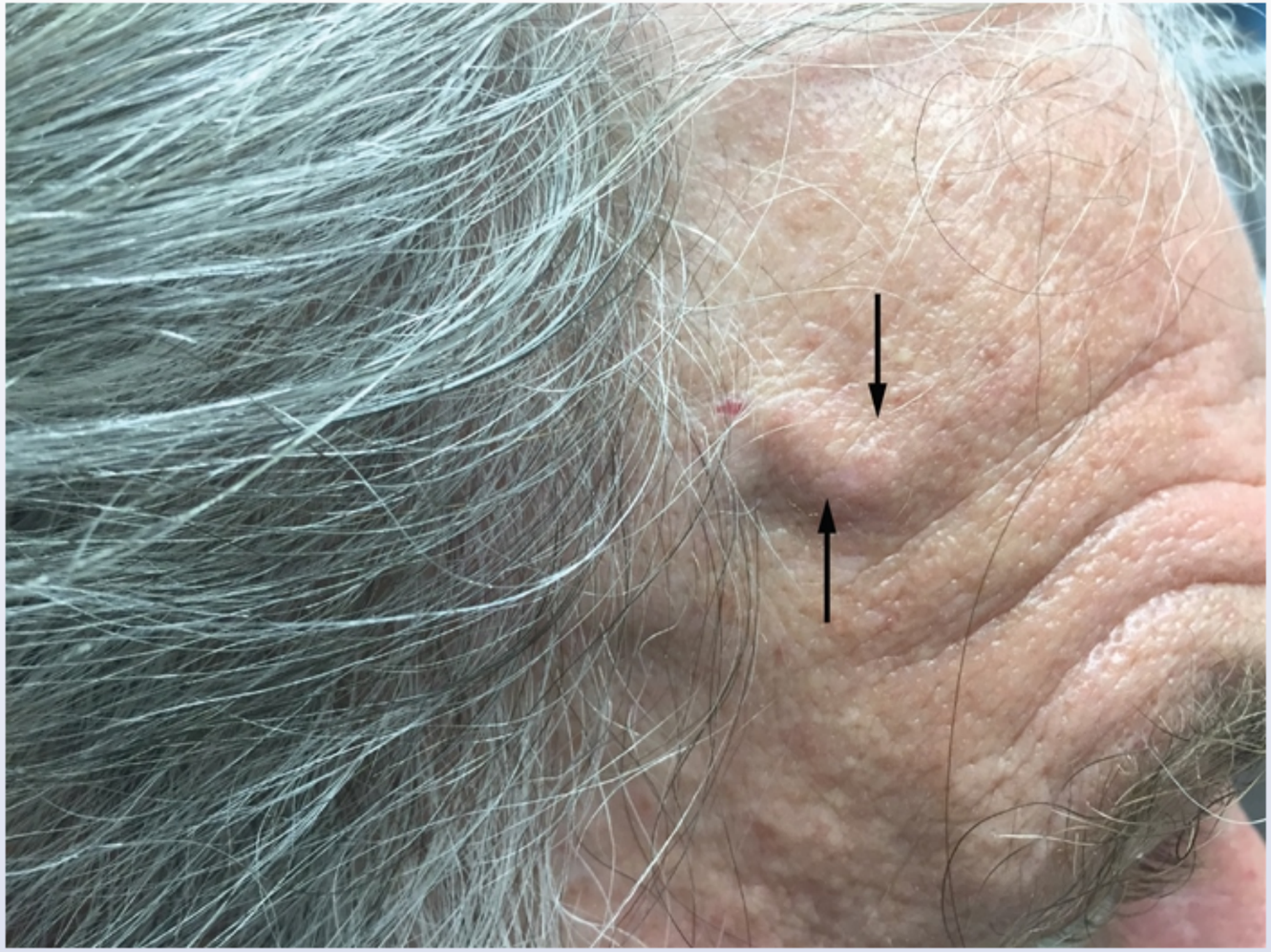

This patient with headaches, visual and muscular symptoms, an enlarged temporal artery, and elevated erythrocyte sedimentation rate has typical features of **giant cell arteritis** ([GCA] temporal arteritis) with associated polymyalgia rheumatica. GCA is the most common systemic vasculitis in persons of Northern European descent and occurs almost exclusively in patients age >50

This patient with headaches, visual and muscular symptoms, an enlarged temporal artery, and elevated erythrocyte sedimentation rate has typical features of **giant cell arteritis** ([GCA] temporal arteritis) with associated polymyalgia rheumatica. GCA is the most common systemic vasculitis in persons of Northern European descent and occurs almost exclusively in patients age >50.

Although both humoral and cellular immune mechanisms have been implicated in the pathogenesis of GCA, cell-mediated processes are of primary importance. The inflammatory infiltrate in affected vessels is composed of lymphocytes (predominantly CD4-positive T cells) and macrophages and frequently contains multinucleated giant cells. The production of cytokines, in particular **interleukin-6** (IL-6), appears to closely correlate with the severity of the disease; a monoclonal antibody against IL-6 (tocilizumab) is effective in treating GCA.

(Choices A and B) Antibodies to myeloperoxidase and proteinase-3 are involved in the pathogenesis of antineutrophil cytoplasmic antibody (ANCA)-associated vasculitides such as microscopic polyangiitis and granulomatosis with polyangiitis.

(Choice C) B cell-activating factor (BAFF) is a cytokine belonging to the tumor necrosis factor ligand family. Inadequate levels of BAFF will lead to immunodeficiency, whereas excess levels can cause autoimmune diseases (eg, systemic lupus erythematosus).

(Choice E) Matrix metalloproteinases are enzymes capable of degrading various extracellular matrix proteins and processing a number of bioactive molecules. They may be involved in cytokine inactivation but do not play a direct role in the pathogenesis of GCA.

Educational objective:
Cell-mediated immunity is the primary mechanism underlying giant cell arteritis. The production of cytokines, in particular interleukin-6, is an important driver of this process and closely correlates with the severity of symptoms.

References

- Pathogenesis of giant cell arteritis: new insight into the implication of CD161+ T cells.
- Pathogenesis of giant cell arteritis: more than just an inflammatory condition?
- New treatment strategies in large-vessel vasculitis.

Pathophysiology	Rheumatology/Orthopedics & Sports	Giant cell arteritis
Subject	System	Topic

Settings

1
2
3
4
5
6
7
8
9
10
11
12
13
14
15
16
17
18
19
20

Item 7 of 20
Question Id: 11770

Mark | Previous | Next | Full Screen | Tutorial | Lab Values | Notes | Calculator | Reverse Color | Text Zoom | Settings

This patient with headaches, visual and muscular symptoms, an enlarged temporal artery, and elevated erythrocyte sedimentation rate has typical

Exhibit Display

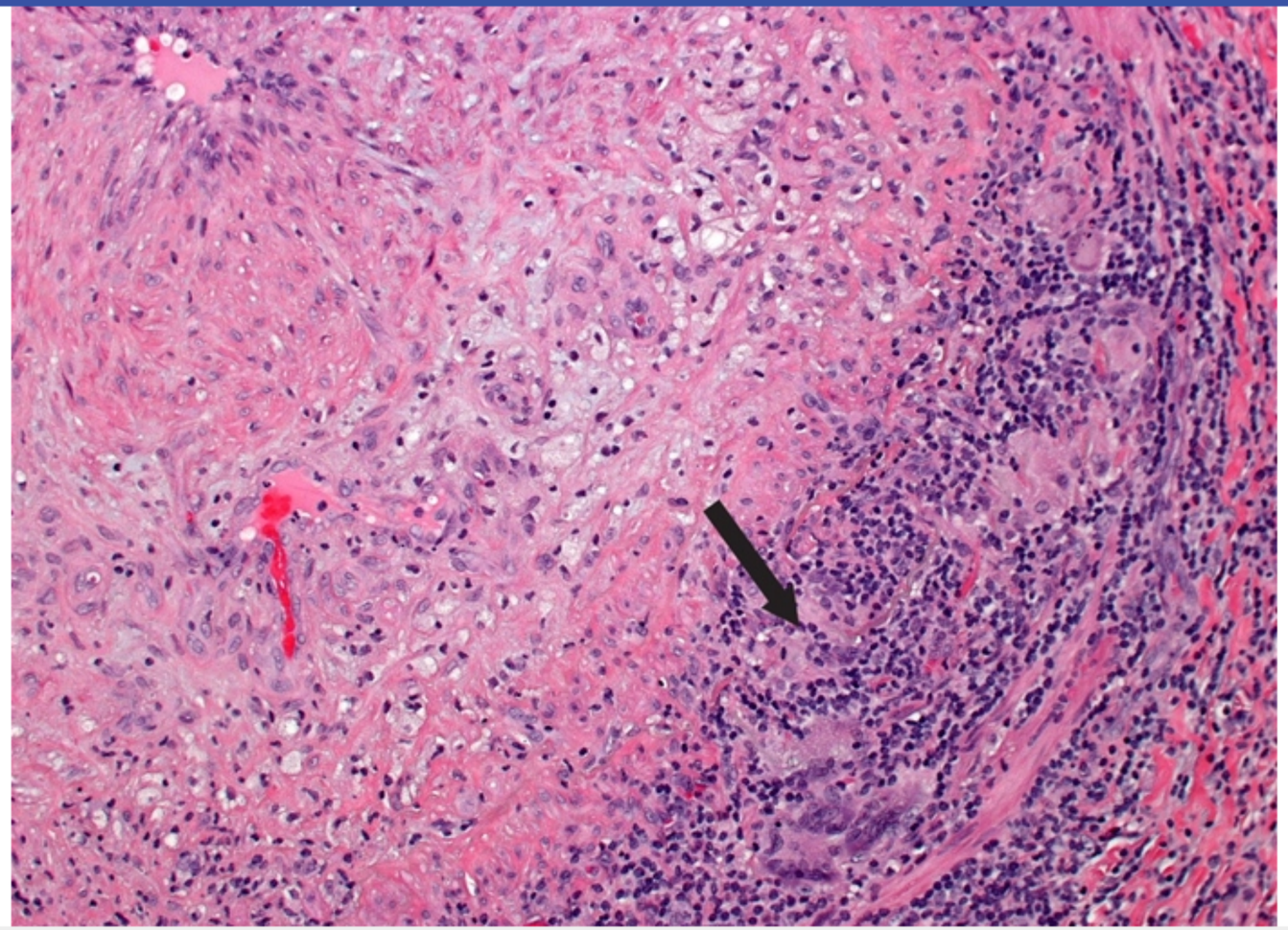

Zoom In | Zoom Out | Reset | Add To New Card | Existing Card

Block Time Remaining: 00:00:37
TUTOR

4 | Feedback | Suspend | End Block

Settings

1
2
3
4
5
6
7
8
9
10
11
12
13
14
15
16
17
18
19
20

Item 8 of 20
Question Id: 740

Mark | Previous | Next | Full Screen | Tutorial | Lab Values | Notes | Calculator | Reverse Color | Text Zoom | Settings

A 34-year-old woman comes to the office with several months of vision problems, difficulty chewing, and trouble speaking. The symptoms fluctuate, but the patient has noticed that they are worse after a long day. She works as a telemarketer and has been putting in increasingly long hours to meet her quotas. Regarding her symptoms, she says, "It's probably just exhaustion; an ice pack to my face seems to help." During physical examination, the patient is asked to keep her eyes focused on a spot on the ceiling, and after 2 minutes, her vision becomes blurry. The remainder of the examination is normal. Further evaluation shows that the patient's symptoms are reversible on administration of an acetylcholinesterase inhibitor. The pathogenesis of this patient's disease is most similar to which of the following conditions?

A. Atopic dermatitis
B. Contact dermatitis
C. Goodpasture syndrome
D. Hypersensitivity pneumonitis
E. Postinfectious glomerulonephritis

Submit

Block Time Remaining: 00:00:38
TUTOR

2 | Feedback | Suspend | End Block

A 34-year-old woman comes to the office with several months of vision problems, difficulty chewing, and trouble speaking. The symptoms fluctuate, but the patient has noticed that they are worse after a long day. She works as a telemarketer and has been putting in increasingly long hours to meet her quotas. Regarding her symptoms, she says, "It's probably just exhaustion; an ice pack to my face seems to help." During physical examination, the patient is asked to keep her eyes focused on a spot on the ceiling, and after 2 minutes, her vision becomes blurry. The remainder of the examination is normal. Further evaluation shows that the patient's symptoms are reversible on administration of an acetylcholinesterase inhibitor. The pathogenesis of this patient's disease is most similar to which of the following conditions?

A. Atopic dermatitis (3%)

B. Contact dermatitis (3%)

✓ C. Goodpasture syndrome (82%)

D. Hypersensitivity pneumonitis (3%)

E. Postinfectious glomerulonephritis (6%)

Omitted
Correct answer
C

82%
Answered correctly

02 secs
Time Spent

06/29/2020
Last Updated

Explanation

This patient's clinical findings of intermittent diplopia, difficulty chewing, and speech problems (especially at the end of the day) suggest a diagnosis of **myasthenia gravis** (MG). MG is caused by impaired functioning of nicotinic cholinergic receptors at the neuromuscular junction due to interference by **IgG autoantibodies**. The diagnosis can be confirmed with administration of an anticholinesterase agent (eg, edrophonium), which increases the amount of acetylcholine at the neuromuscular junction. Acetylcholinesterase activity decreases at lower temperatures, so

This patient's clinical findings of intermittent diplopia, difficulty chewing, and speech problems (especially at the end of the day) suggest a diagnosis of **myasthenia gravis** (MG). MG is caused by impaired functioning of nicotinic cholinergic receptors at the neuromuscular junction due to interference by **IgG autoantibodies**. The diagnosis can be confirmed with administration of an anticholinesterase agent (eg, edrophonium), which increases the amount of acetylcholine at the neuromuscular junction. Acetylcholinesterase activity decreases at lower temperatures, so application of an ice pack can also improve symptoms caused by weakness of superficial muscles (eg, ptosis).

MG is a form of **type II hypersensitivity**, which is characterized by IgM and/or IgG autoantibodies that bind to cell surface antigens and/or extracellular matrix components. Among the available options, only Goodpasture syndrome is due to the production of autoantibodies (directed against the glomerular basement membrane). These antibodies cause inflammatory destruction of the basement membrane in the lung alveoli and renal glomeruli.

(Choice A) Atopic dermatitis is a chronic, pruritic, eczematous skin condition that almost always begins in childhood. The pathogenicity involves several factors, including skin barrier abnormalities, defects in innate immunity, and a T_H2-skewed immune response.

(Choice B) The pathogenesis of contact dermatitis (type IV hypersensitivity reaction) involves cutaneous exposure to small foreign molecules (haptens) that bind to skin proteins. These proteins are subsequently processed by antigen-presenting Langerhans cells that transport the modified proteins to lymph nodes and promote the development of hapten-specific T cells. With continued hapten exposure, sensitized T cells produce inflammatory cytokines at the exposure site, causing the characteristic eczematous skin changes.

(Choice D) Most patients with acute hypersensitivity pneumonitis have specific serum IgG antibodies that precipitate bacterial or fungal antigens found in inhaled organic dust particles. This causes interstitial alveolitis and bronchiolitis via immune complex and complement deposition in vessel walls (type III hypersensitivity mechanism).

(Choice E) The pathogenesis of poststreptococcal glomerulonephritis involves granular deposition of immune complexes containing group A streptococcal antigens, IgG, and C3 in the glomerular basement membrane and mesangium. It is a type III, immune complex-mediated, hypersensitivity response.

Educational objective:
Myasthenia gravis results from an autoimmune type II (antibody-mediated) hypersensitivity reaction against skeletal myocyte surface acetylcholine receptors. Goodpasture syndrome similarly involves autoantibodies against basement membrane collagen in the renal glomeruli and lung alveoli.

MG is a form of **type II hypersensitivity**, which is characterized by IgM and/or IgG autoantibodies that bind to cell surface antigens and/or extracellular matrix components. Among the available options, only Goodpasture syndrome is due to the production of autoantibodies (directed against the glomerular basement membrane). These antibodies cause inflammatory destruction of the basement membrane in the lung alveoli and renal glomeruli.

(Choice A) Atopic dermatitis is a chronic, pruritic, eczematous skin condition that almost always begins in childhood. The pathogenicity involves several factors, including skin barrier abnormalities, defects in innate immunity, and a T_H2-skewed immune response.

(Choice B) The pathogenesis of contact dermatitis (type IV hypersensitivity reaction) involves cutaneous exposure to small foreign molecules (haptens) that bind to skin proteins. These proteins are subsequently processed by antigen-presenting Langerhans cells that transport the modified proteins to lymph nodes and promote the development of hapten-specific T cells. With continued hapten exposure, sensitized T cells produce inflammatory cytokines at the exposure site, causing the characteristic eczematous skin changes.

(Choice D) Most patients with acute hypersensitivity pneumonitis have specific serum IgG antibodies that precipitate bacterial or fungal antigens found in inhaled organic dust particles. This causes interstitial alveolitis and bronchiolitis via immune complex and complement deposition in vessel walls (type III hypersensitivity mechanism).

(Choice E) The pathogenesis of poststreptococcal glomerulonephritis involves granular deposition of immune complexes containing group A streptococcal antigens, IgG, and C3 in the glomerular basement membrane and mesangium. It is a type III, immune complex-mediated, hypersensitivity response.

Educational objective:
Myasthenia gravis results from an autoimmune type II (antibody-mediated) hypersensitivity reaction against skeletal myocyte surface acetylcholine receptors. Goodpasture syndrome similarly involves autoantibodies against basement membrane collagen in the renal glomeruli and lung alveoli.

Pathophysiology	Rheumatology/Orthopedics & Sports	Myasthenia gravis
Subject	System	Topic

Copyright © UWorld. All rights reserved.

Settings

1
2
3
4
5
6
7
8
9
10
11
12
13
14
15
16
17
18
19
20

Item 9 of 20
Question Id: 753

Mark | Previous | Next | Full Screen | Tutorial | Lab Values | Notes | Calculator | Reverse Color | Text Zoom | Settings

A 34-year-old man comes to the office due to progressive low back pain for several years. The patient reports that the stiffness and pain are worst in the morning but gradually improve during the day. Lately, he has been taking over-the-counter ibuprofen, which provides some relief. Laboratory evaluation shows a positive HLA-B27 antigen. X-ray imaging reveals fusion of the sacroiliac joints. Which of the following is most helpful to monitor disease progression in this patient?

A. Degree of chest expansion
B. Hand joint mobility
C. Peak expiratory flow rate
D. Rheumatoid factor level
E. Urine protein level

Submit

Block Time Remaining: 00:00:39
TUTOR

5 | Feedback | Suspend | End Block

A 34-year-old man comes to the office due to progressive low back pain for several years. The patient reports that the stiffness and pain are worst in the morning but gradually improve during the day. Lately, he has been taking over-the-counter ibuprofen, which provides some relief. Laboratory evaluation shows a positive HLA-B27 antigen. X-ray imaging reveals fusion of the sacroiliac joints. Which of the following is most helpful to monitor disease progression in this patient?

- ✓ A. Degree of chest expansion (40%)
- B. Hand joint mobility (16%)
- C. Peak expiratory flow rate (11%)
- D. Rheumatoid factor level (20%)
- E. Urine protein level (10%)

Omitted
Correct answer
A

40%
Answered correctly

02 secs
Time Spent

01/19/2020
Last Updated

Explanation

Symptoms/signs of ankylosing spondylitis
• Low back pain (onset age <40, insidious onset, improves with exercise but not with rest, pain at night)

Explanation

Symptoms/signs of ankylosing spondylitis
• Low back pain (onset age <40, insidious onset, improves with exercise but not with rest, pain at night) • Hip & buttock pain • Limited chest expansion & spinal mobility • Enthesitis (inflammation at the site of insertion of a tendon to the bone) • Systemic symptoms (eg, fever, chills, fatigue, weight loss) • Acute anterior uveitis (unilateral pain, photophobia, blurry vision)

©UWorld

The symptoms of low back pain and morning stiffness in a young man suggest **ankylosing spondylitis** (AS), a chronic inflammatory condition associated with the HLA-B27 serotype. AS is characterized by stiffness and fusion (**ankylosis**) of the axial joints. The sacroiliac and apophyseal joints of the spine are the most commonly affected, leading to restricted spinal mobility. Many patients also develop peripheral arthritis and **enthesitis**, which is defined as pain, tenderness, and swelling at the sites of tendon insertion into bone (eg, Achilles tendon insertion).

In addition, AS can cause complications in extraskeletal systems:

1. **Respiratory**: Involvement of the thoracic spine and enthesopathies of the costovertebral and costosternal junctions can limit chest wall expansion, leading to hypoventilation. Chest expansion should be monitored regularly in patients with AS.
2. **Cardiovascular**: The most common cardiovascular complication of AS is ascending aortitis, which can lead to dilation of the aortic ring and aortic insufficiency.
3. **Eye**: Anterior uveitis develops in some patients with AS and presents with pain, blurred vision, photophobia, and conjunctival erythema.

(Choice B) Hand joint mobility testing is part of the assessment of rheumatoid arthritis severity. However, the small joints of the hands are not

- Acute anterior uveitis (unilateral pain, photophobia, blurry vision)

©UWorld

The symptoms of low back pain and morning stiffness in a young man suggest **ankylosing spondylitis** (AS), a chronic inflammatory condition associated with the HLA-B27 serotype. AS is characterized by stiffness and fusion (**ankylosis**) of the axial joints. The sacroiliac and apophyseal joints of the spine are the most commonly affected, leading to restricted spinal mobility. Many patients also develop peripheral arthritis and **enthesitis**, which is defined as pain, tenderness, and swelling at the sites of tendon insertion into bone (eg, Achilles tendon insertion).

In addition, AS can cause complications in extraskeletal systems:

1. **Respiratory**: Involvement of the thoracic spine and enthesopathies of the costovertebral and costosternal junctions can limit chest wall expansion, leading to hypoventilation. Chest expansion should be monitored regularly in patients with AS.
2. **Cardiovascular**: The most common cardiovascular complication of AS is ascending aortitis, which can lead to dilation of the aortic ring and aortic insufficiency.
3. **Eye**: Anterior uveitis develops in some patients with AS and presents with pain, blurred vision, photophobia, and conjunctival erythema.

(Choice B) Hand joint mobility testing is part of the assessment of rheumatoid arthritis severity. However, the small joints of the hands are not prominently affected by AS.

(Choice C) Peak expiratory flow is determined by airway resistance (obstruction) and chest and abdominal wall muscular function. These variables are not affected by chest wall restriction and are normal in AS. Regular measurement of expiratory flow rates is important in patients with asthma.

(Choice D) Rheumatoid factor can be found in a variety of rheumatic (eg, rheumatoid arthritis, Sjögren's syndrome, systemic lupus erythematosus [SLE]) and nonrheumatic disorders (eg, hepatitis C) and in up to 4% of young and healthy individuals. However, it is not associated with AS.

(Choice E) Urine protein excretion should be monitored in SLE and diabetes mellitus. Renal involvement is rare in AS.

Educational objective:
Ankylosing spondylitis is characterized by stiffness and fusion of axial joints (ankylosis) and inflammation at the site of insertion of tendons into

Settings

1
2
3
4
5
6
7
8
9
10
11
12
13
14
15
16
17
18
19
20

Item 9 of 20
Question Id: 753

Mark | Previous | Next | Full Screen | Tutorial | Lab Values | Notes | Calculator | Reverse Color | Text Zoom | Settings

- Acute anterior uveitis (unilateral pain, photophobia, blurry vision)

Exhibit Display

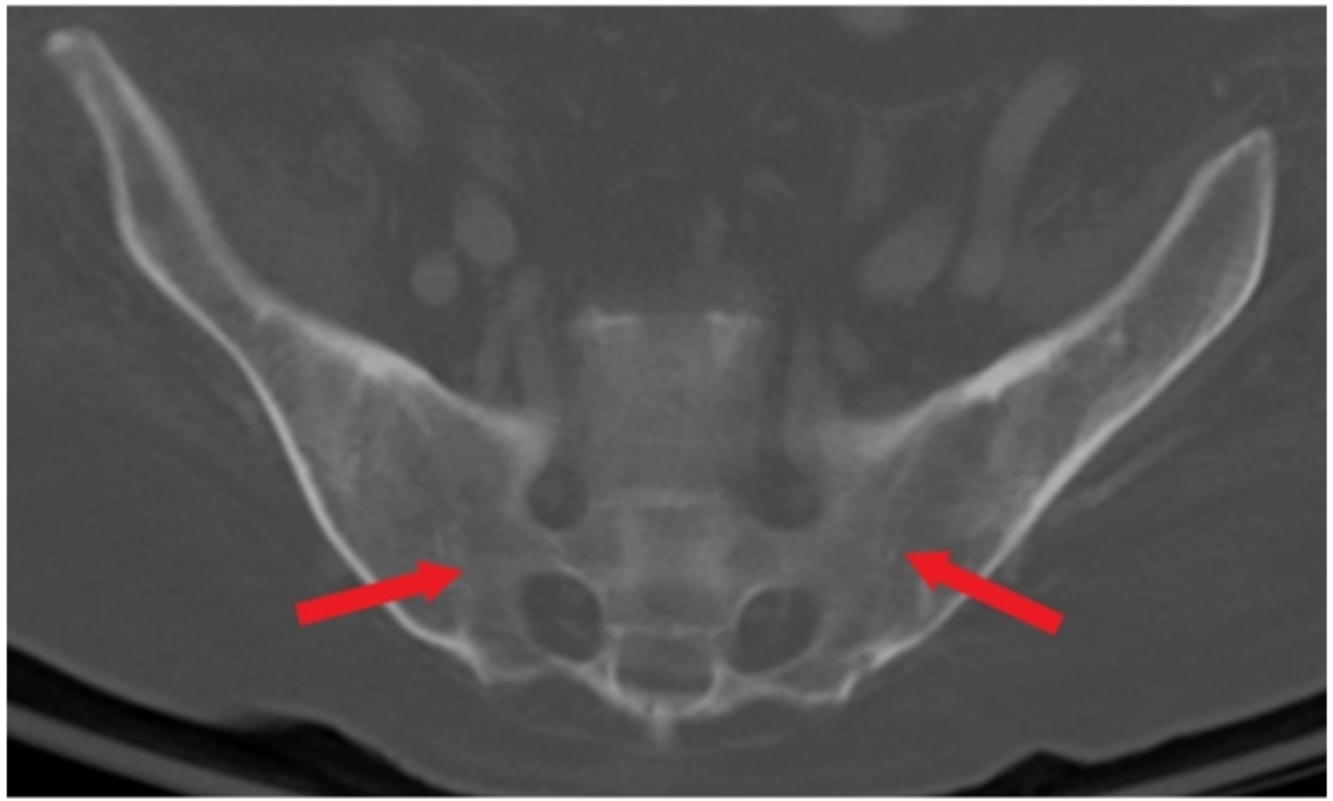

Zoom In | Zoom Out | Reset | Add To New Card | Existing Card

Ankylosing spondylitis is characterized by stiffness and fusion of axial joints (ankylosis) and inflammation at the site of insertion of tendons into

Block Time Remaining: 00:00:41
TUTOR

5 | Feedback | Suspend | End Block

Settings

1
2
3
4
5
6
7
8
9
10
11
12
13
14
15
16
17
18
19
20

Item 9 of 20
Question Id: 753

Mark | Previous | Next | Full Screen | Tutorial | Lab Values | Notes | Calculator | Reverse Color | Text Zoom | Settings

- Acute anterior uveitis (unilateral pain, photophobia, blurry vision)

Exhibit Display

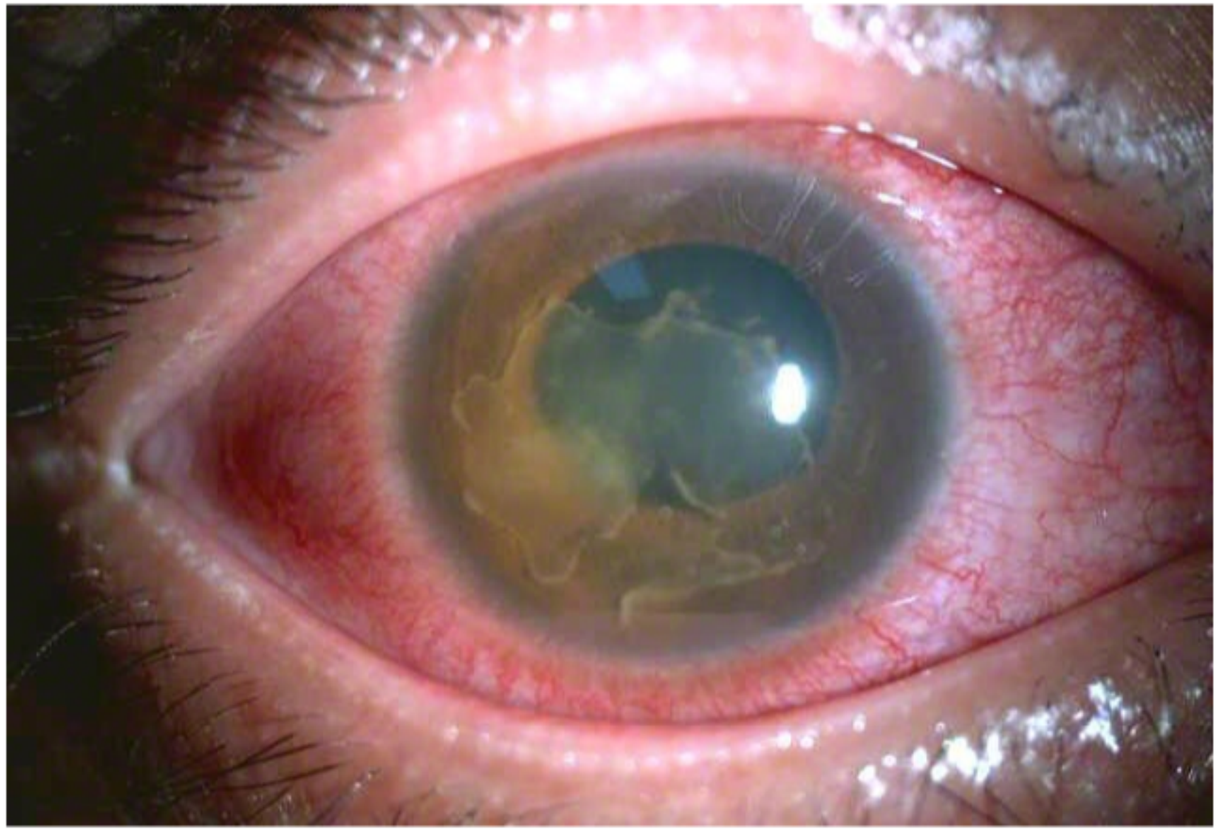

Zoom In | Zoom Out | Reset | Add To New Card | Existing Card

Ankylosing spondylitis is characterized by stiffness and fusion of axial joints (ankylosis) and inflammation at the site of insertion of tendons into

Block Time Remaining: 00:00:41
TUTOR

5 | Feedback | Suspend | End Block

2. **Cardiovascular**: The most common cardiovascular complication of AS is ascending aortitis, which can lead to dilation of the aortic ring and aortic insufficiency.
3. **Eye**: Anterior uveitis develops in some patients with AS and presents with pain, blurred vision, photophobia, and conjunctival erythema.

(Choice B) Hand joint mobility testing is part of the assessment of rheumatoid arthritis severity. However, the small joints of the hands are not prominently affected by AS.

(Choice C) Peak expiratory flow is determined by airway resistance (obstruction) and chest and abdominal wall muscular function. These variables are not affected by chest wall restriction and are normal in AS. Regular measurement of expiratory flow rates is important in patients with asthma.

(Choice D) Rheumatoid factor can be found in a variety of rheumatic (eg, rheumatoid arthritis, Sjögren's syndrome, systemic lupus erythematosus [SLE]) and nonrheumatic disorders (eg, hepatitis C) and in up to 4% of young and healthy individuals. However, it is not associated with AS.

(Choice E) Urine protein excretion should be monitored in SLE and diabetes mellitus. Renal involvement is rare in AS.

Educational objective:
Ankylosing spondylitis is characterized by stiffness and fusion of axial joints (ankylosis) and inflammation at the site of insertion of tendons into bone (enthesitis). Involvement of the thoracic spine and costovertebral and costosternal junctions can limit chest wall expansion, leading to hypoventilation.

References

- Restrictive pulmonary function is more prevalent in patients with ankylosing spondylitis than in matched population controls and is associated with impaired spinal mobility: a comparative study.

Pathophysiology	Rheumatology/Orthopedics & Sports	Ankylosing spondylitis
Subject	System	Topic

Copyright © UWorld. All rights reserved.

Settings

1
2
3
4
5
6
7
8
9
10
11
12
13
14
15
16
17
18
19
20

Item 10 of 20
Question Id: 867

Mark | Previous | Next | Full Screen | Tutorial | Lab Values | Notes | Calculator | Reverse Color | Text Zoom | Settings

A 45-year-old woman comes to the clinic with a 3-month history of persistent shoulder and back pain and easy fatigability. She also has pain and stiffness in all her muscles that worsens in the morning and evening. She does not participate in any regular exercise because her pain is exacerbated with activity. She works as a computer programmer and reports some difficulty concentrating on her job. Past medical history is significant for depression and gastroesophageal reflux disease, but she is not currently taking any medications. Physical examination shows normal range of motion and 5/5 muscle strength in both upper and lower extremities. Soft tissue tenderness is present at several locations bilaterally above and below the waist. Which of the following is the most likely diagnosis?

A. Ankylosing spondylitis
B. Dermatomyositis
C. Fibromyalgia
D. Polymyalgia rheumatica
E. Rheumatoid arthritis

Submit

Block Time Remaining: 00:00:42
TUTOR

3 | Feedback | Suspend | End Block

A 45-year-old woman comes to the clinic with a 3-month history of persistent shoulder and back pain and easy fatigability. She also has pain and stiffness in all her muscles that worsens in the morning and evening. She does not participate in any regular exercise because her pain is exacerbated with activity. She works as a computer programmer and reports some difficulty concentrating on her job. Past medical history is significant for depression and gastroesophageal reflux disease, but she is not currently taking any medications. Physical examination shows normal range of motion and 5/5 muscle strength in both upper and lower extremities. Soft tissue tenderness is present at several locations bilaterally above and below the waist. Which of the following is the most likely diagnosis?

- A. Ankylosing spondylitis (2%)
- B. Dermatomyositis (2%)
- ✓ C. Fibromyalgia (71%)
- D. Polymyalgia rheumatica (20%)
- E. Rheumatoid arthritis (2%)

Omitted
Correct answer
C

71%
Answered correctly

02 secs
Time Spent

01/21/2020
Last Updated

Explanation

Clinical features of fibromyalgia	
	• **Widespread musculoskeletal pain**

Clinical features of fibromyalgia	
Symptoms	• **Widespread musculoskeletal pain** • **Fatigue** • Impaired attention & concentration • Psychiatric disturbances (eg, depression, anxiety) • Symptoms lasting for ≥3 months
Physical examination	• Multiple tender points at characteristic locations • Absence of joint or muscle inflammation
Laboratory findings	• Normal acute phase reactants (eg, ESR, CRP) & other inflammatory markers
Treatment	• Progressive **exercise** regimen • **Medications:** tricyclic antidepressants, cyclic skeletal muscle relaxants, serotonin-norepinephrine reuptake inhibitors

CRP = C-reactive protein; ESR = erythrocyte sedimentation rate.

Fibromyalgia is a chronic disorder that is characterized by **widespread musculoskeletal pain** in association with **fatigue** and neuropsychiatric disturbances (eg, paresthesias, poor sleep, depression, difficulty concentrating). It is most common in women age 20-55. Examination often shows tenderness at characteristic locations in the soft tissues and at bony prominences. The diagnosis can be made in patients with chronic pain and fatigue for >3 months in the absence of physical or laboratory findings suggestive of an inflammatory etiology (eg, synovial swelling, elevated erythrocyte sedimentation rate or C-reactive protein) or other chronic pain syndrome.

The precise etiology of fibromyalgia is unknown, but it likely involves **abnormal central processing** of painful stimuli. Possible contributing factors include genetic predisposition and physical or emotional stressors. Although exercise can temporarily exacerbate the pain of fibromyalgia, gradual **incremental aerobic exercise** is proven to reduce pain and improve function. Tricyclic antidepressants and serotonin-norepinephrine reuptake inhibitors modify processing of pain signals and can also be considered in patients with more severe or refractory symptoms.

(Choice A) Ankylosing spondylitis is a chronic inflammatory disease of the axial skeleton characterized by progressive pain and stiffness of the

Fibromyalgia is a chronic disorder that is characterized by **widespread musculoskeletal pain** in association with **fatigue** and neuropsychiatric disturbances (eg, paresthesias, poor sleep, depression, difficulty concentrating). It is most common in women age 20-55. Examination often shows tenderness at characteristic locations in the soft tissues and at bony prominences. The diagnosis can be made in patients with chronic pain and fatigue for >3 months in the absence of physical or laboratory findings suggestive of an inflammatory etiology (eg, synovial swelling, elevated erythrocyte sedimentation rate or C-reactive protein) or other chronic pain syndrome.

The precise etiology of fibromyalgia is unknown, but it likely involves **abnormal central processing** of painful stimuli. Possible contributing factors include genetic predisposition and physical or emotional stressors. Although exercise can temporarily exacerbate the pain of fibromyalgia, gradual **incremental aerobic exercise** is proven to reduce pain and improve function. Tricyclic antidepressants and serotonin-norepinephrine reuptake inhibitors modify processing of pain signals and can also be considered in patients with more severe or refractory symptoms.

(Choice A) Ankylosing spondylitis is a chronic inflammatory disease of the axial skeleton characterized by progressive pain and stiffness of the spine, sacroiliitis, and positive serology for HLA-B27 in the majority of patients.

(Choice B) Dermatomyositis is an autoimmune condition that causes bilateral proximal muscle weakness associated with violaceous eruption on the eyelids and knuckles, and elevated creatine kinase levels.

(Choice D) Polymyalgia rheumatica (PMR) is an inflammatory disorder that affects patients age ≥50 and causes subacute pain and stiffness in the shoulders and hips, weight loss, fever, and malaise. This patient's age, soft tissue tenderness, and neuropsychiatric symptoms are not consistent with PMR but are typical of fibromyalgia.

(Choice E) Rheumatoid arthritis causes a symmetric, inflammatory polyarthritis. It typically presents with pain and morning stiffness of the metacarpophalangeal and proximal interphalangeal joints. The affected joints are warm, swollen, and tender on palpation.

Educational objective:
Fibromyalgia occurs most commonly in women age 20-55 and presents with diffuse musculoskeletal pain, fatigue, and neuropsychiatric disturbances. It is characterized by abnormal central processing of painful stimuli. Although initially painful, aerobic exercise helps to improve pain and functioning in these patients.

References

- Fibromyalgia syndrome: etiology, pathogenesis, diagnosis, and treatment

Settings

1
2
3
4
5
6
7
8
9
10
11
12
13
14
15
16
17
18
19
20

Item 11 of 20
Question Id: 987

Mark | Previous | Next | Full Screen | Tutorial | Lab Values | Notes | Calculator | Reverse Color | Text Zoom | Settings

A 70-year-old man comes to the clinic due to intermittent leg pain and difficulty walking. He describes the pain as mild-to-moderate, deep, and lasting throughout the day. The patient has a history of osteoarthritis in his hands for which he takes over-the-counter nonsteroidal anti-inflammatory drugs, but says that he never has had problems with his knees. Physical examination shows point tenderness over the right tibia. Laboratory studies show elevated serum alkaline phosphatase. Bone biopsy shows haphazardly oriented segments of lamellar bone with prominent cement lines. The initial phase of this patient's disorder involves increased activity of which of the following cell types?

A. Chondrocytes
B. Endothelial cells
C. Fibroblasts
D. Osteoblasts
E. Osteoclasts

Submit

Block Time Remaining: 00:00:43
TUTOR

3 | Feedback | Suspend | End Block

A 70-year-old man comes to the clinic due to intermittent leg pain and difficulty walking. He describes the pain as mild-to-moderate, deep, and lasting throughout the day. The patient has a history of osteoarthritis in his hands for which he takes over-the-counter nonsteroidal anti-inflammatory drugs, but says that he never has had problems with his knees. Physical examination shows point tenderness over the right tibia. Laboratory studies show elevated serum alkaline phosphatase. Bone biopsy shows haphazardly oriented segments of lamellar bone with prominent cement lines. The initial phase of this patient's disorder involves increased activity of which of the following cell types?

A. Chondrocytes (3%)
B. Endothelial cells (0%)
C. Fibroblasts (1%)
D. Osteoblasts (26%)
✓ E. Osteoclasts (68%)

Omitted
Correct answer
E

68%
Answered correctly

01 sec
Time Spent

03/03/2020
Last Updated

Explanation

This elderly patient's bone pain, increased alkaline phosphatase, and biopsy findings are characteristic of **Paget disease of bone** (PDB), a condition that results in accelerated bone remodeling with eventual bony overgrowth. The disease is thought to be caused by environmental factors and gene mutations (eg, affecting RANK, osteoprotegerin) that result in excessive RANK and NF-κB activation. This leads to increased osteoclast differentiation and activity. The disease typically progresses through 3 phases:

Settings

1
2
3
4
5
6
7
8
9
10
11
12
13
14
15
16
17
18
19
20

Item 11 of 20
Question Id: 987

Mark | Previous | Next | Full Screen | Tutorial | Lab Values | Notes | Calculator | Reverse Color | Text Zoom | Settings

Paget disease of bone

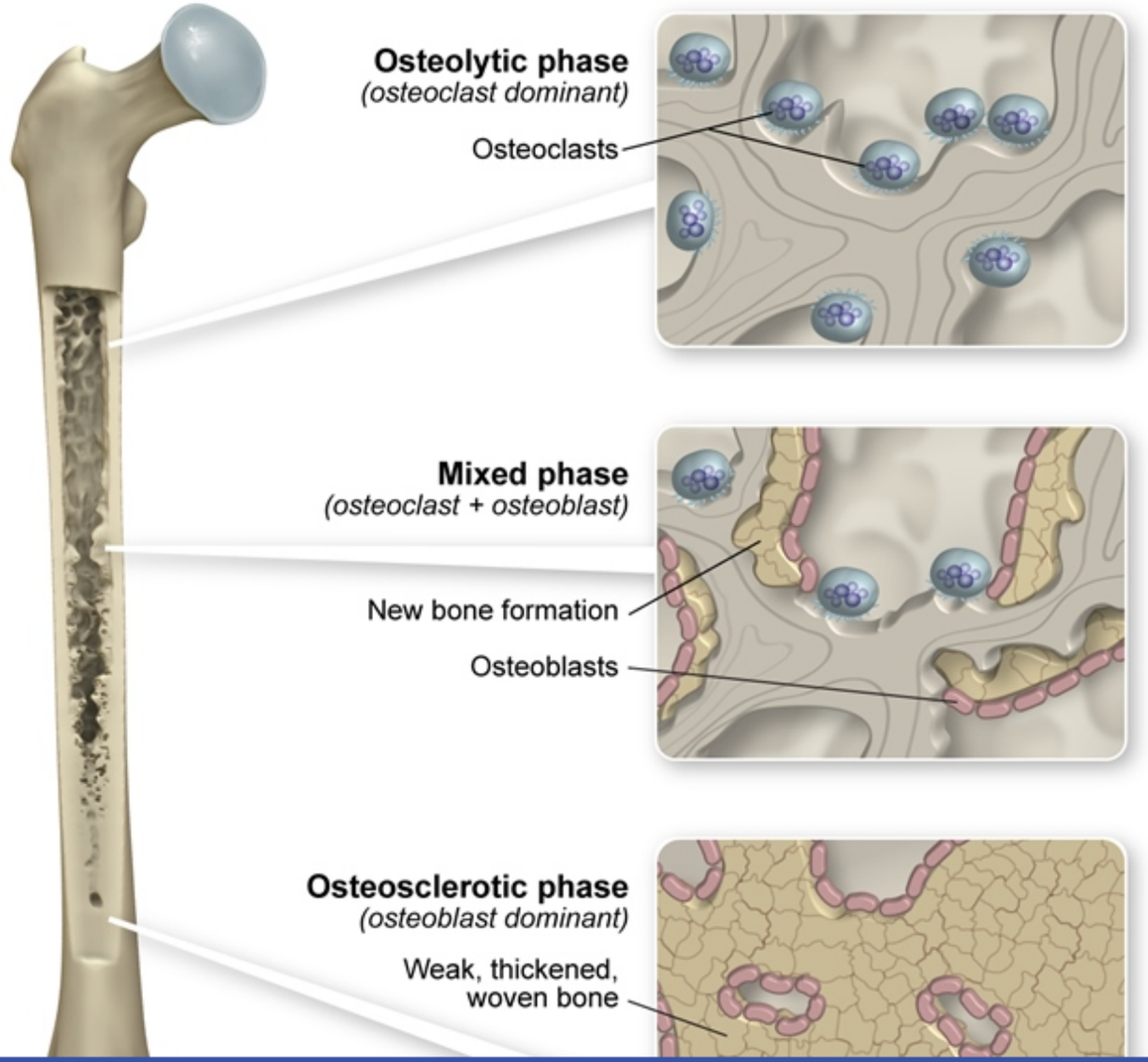

Block Time Remaining: 00:00:44
TUTOR

3 | Feedback | Suspend | End Block

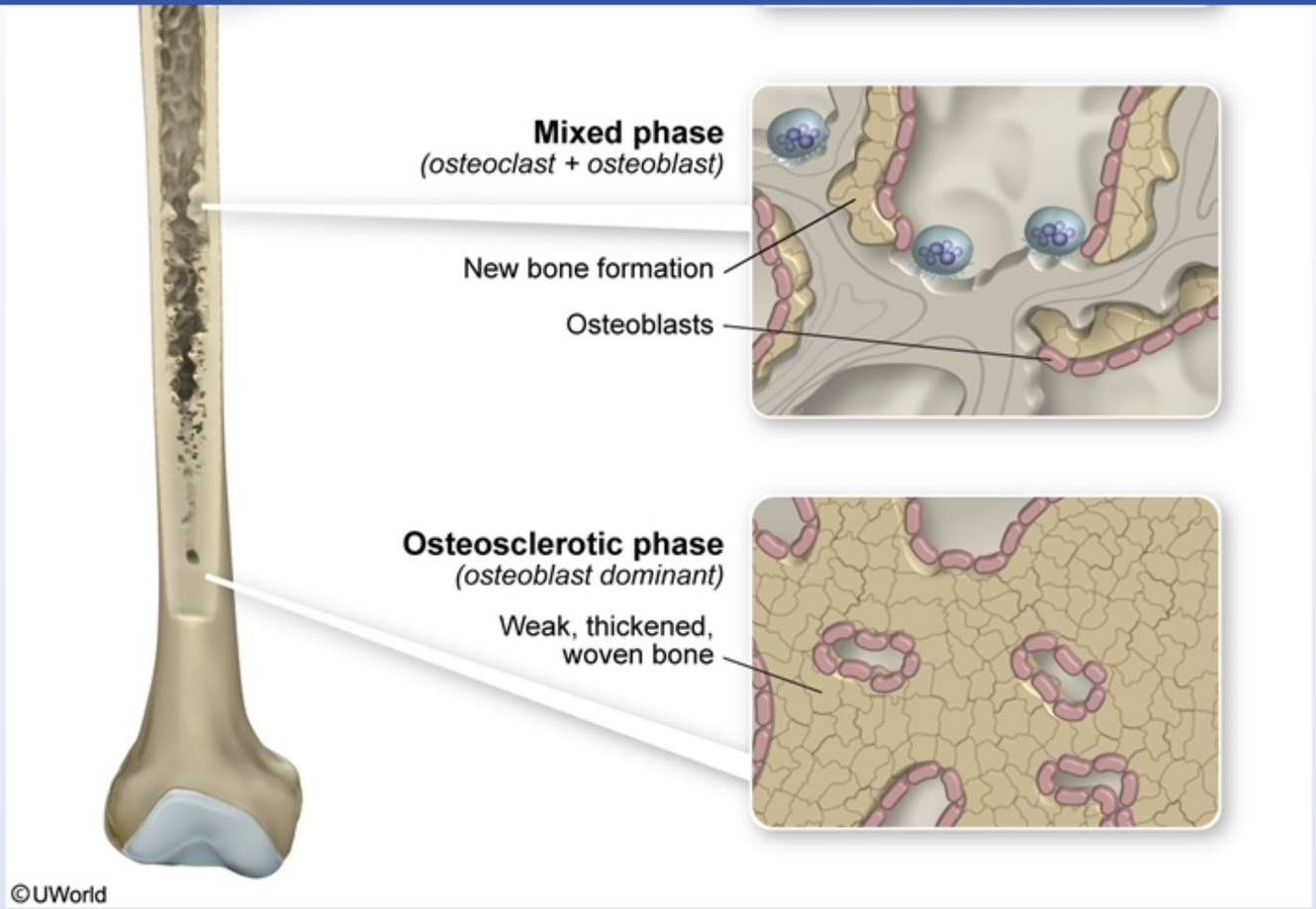

This elderly patient's bone pain, increased alkaline phosphatase, and biopsy findings are characteristic of **Paget disease of bone** (PDB), a condition that results in accelerated bone remodeling with eventual bony overgrowth. The disease is thought to be caused by environmental factors and gene mutations (eg, affecting RANK, osteoprotegerin) that result in excessive RANK and NF-κB activation. This leads to increased osteoclast differentiation and activity. The disease typically progresses through 3 phases:

1. **Osteolytic (osteoclast-dominant) phase** – characterized by increased numbers of osteoclasts that appear abnormally large with an

This elderly patient's bone pain, increased alkaline phosphatase, and biopsy findings are characteristic of **Paget disease of bone** (PDB), a condition that results in accelerated bone remodeling with eventual bony overgrowth. The disease is thought to be caused by environmental factors and gene mutations (eg, affecting RANK, osteoprotegerin) that result in excessive RANK and NF-κB activation. This leads to increased osteoclast differentiation and activity. The disease typically progresses through 3 phases:

1. **Osteolytic (osteoclast-dominant) phase** – characterized by increased numbers of osteoclasts that appear abnormally large with an excessive number of nuclei. Increased resorption activity is prominent.
2. Mixed (osteoclastic-osteoblastic) phase – defined by a rapid increase in osteoblastic bone formation with persistent osteoclastic activity. The newly made bone is abnormal, with interspersed areas of disorganized lamellar and woven bone.
3. **Osteosclerotic (osteoblast-dominant) phase** – characterized by continued osteoblastic bone formation and remodelling that result in a dense, hypovascular, **mosaic pattern** of lamellar bone with irregular, haphazardly oriented sections separated by **prominent cement lines**.

The end result is a thickened, deformed bone that is weaker than normal and prone to fracture.

(Choice A) Chondrocytes are not involved in the pathogenesis of PDB.

(Choices B and C) In the early stages of PDB, the adjacent marrow spaces are replaced by highly vascular stromal tissue as a result of increased endothelial cell and fibroblast proliferation due to cytokines secreted by osteoclasts. The increased vascularity causes arteriovenous shunting that can result in high-output heart failure.

(Choice D) Although this patient's bone biopsy shows findings characteristic of the osteosclerotic (osteoblast-dominant) phase of Paget disease, the question is specifically asking about the **initial (osteolytic) phase** of Paget disease, where osteoclast activity is predominantly increased. Increased activity and dysregulation of osteoblasts and fibroblasts increase the risk of developing sarcomas (eg, osteosarcoma) in patients with PDB.

Educational objective:
Bone pain and elevated alkaline phosphatase level in an elderly patient can occur with osteoblast metastases and Paget disease of bone (PDB). Biopsy showing a mosaic pattern of lamellar bone is diagnostic for PDB. The initial phase in PDB is characterized by an increase in osteoclastic activity.

The newly made bone is abnormal, with interspersed areas of disorganized lamellar and woven bone.

3. **Osteosclerotic (osteoblast-dominant) phase** – characterized by continued osteoblastic bone formation and remodelling that result in a dense, hypovascular, **mosaic pattern** of lamellar bone with irregular, haphazardly oriented sections separated by **prominent cement lines**.

The end result is a thickened, deformed bone that is weaker than normal and prone to fracture.

(Choice A) Chondrocytes are not involved in the pathogenesis of PDB.

(Choices B and C) In the early stages of PDB, the adjacent marrow spaces are replaced by highly vascular stromal tissue as a result of increased endothelial cell and fibroblast proliferation due to cytokines secreted by osteoclasts. The increased vascularity causes arteriovenous shunting that can result in high-output heart failure.

(Choice D) Although this patient's bone biopsy shows findings characteristic of the osteosclerotic (osteoblast-dominant) phase of Paget disease, the question is specifically asking about the **initial (osteolytic) phase** of Paget disease, where osteoclast activity is predominantly increased. Increased activity and dysregulation of osteoblasts and fibroblasts increase the risk of developing sarcomas (eg, osteosarcoma) in patients with PDB.

Educational objective:
Bone pain and elevated alkaline phosphatase level in an elderly patient can occur with osteoblast metastases and Paget disease of bone (PDB). Biopsy showing a mosaic pattern of lamellar bone is diagnostic for PDB. The initial phase in PDB is characterized by an increase in osteoclastic activity.

References

- Pathogenesis of Paget's disease of bone.

Pathophysiology	Rheumatology/Orthopedics & Sports	Pagets disease of bone
Subject	System	Topic

Copyright © UWorld. All rights reserved.

woven bone

Exhibit Display

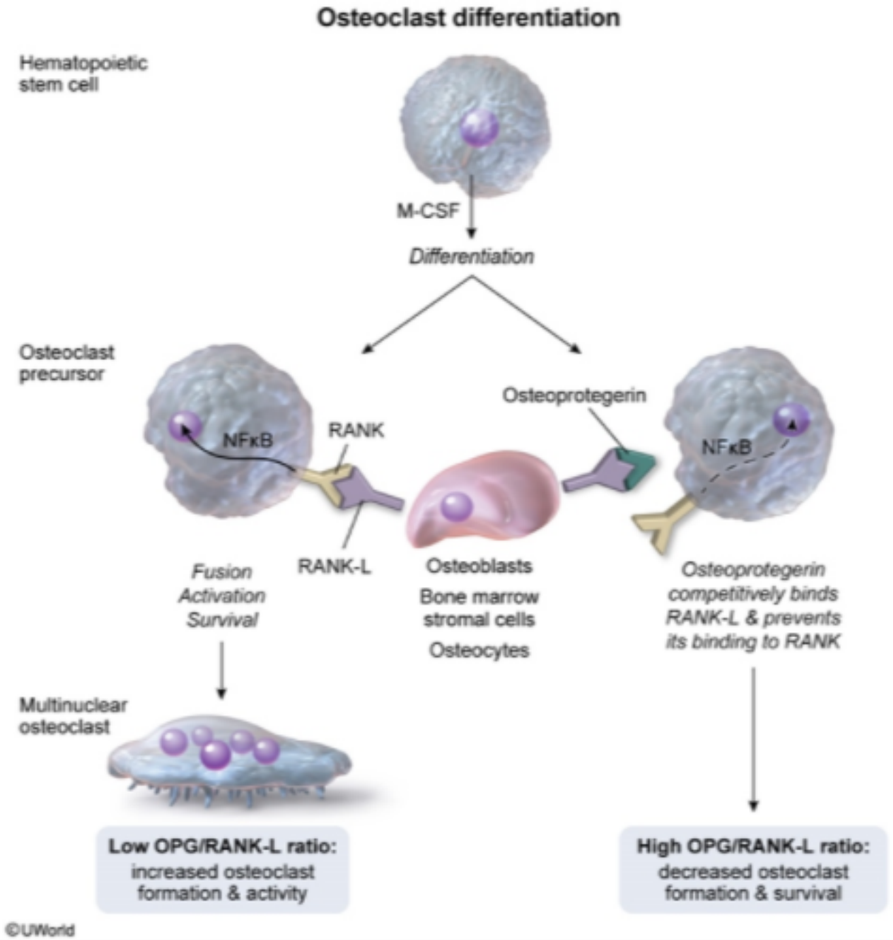

Zoom In | Zoom Out | Reset | Add To New Card | Existing Card

Increased activity and dysregulation of osteoblasts and fibroblasts increase the risk of developing sarcomas (eg, osteosarcoma) in patients with

Settings

1
2
3
4
5
6
7
8
9
10
11
12
13
14
15
16
17
18
19
20

Item 12 of 20
Question Id: 8802

Mark | Previous | Next | Full Screen | Tutorial | Lab Values | Notes | Calculator | Reverse Color | Text Zoom | Settings

A 47-year-old woman comes to the physician with progressive joint pain and swelling in her hands for the past several months. She also has easy fatigability that has gradually worsened over the same period. Morning activities are especially difficult due to stiffness lasting 1 to 2 hours after waking. Examination shows warmth, swelling, and tenderness involving the proximal interphalangeal joints, metacarpophalangeal joints, and wrists bilaterally. A blood sample is obtained for laboratory analysis. Autoantibodies against which of the following components are most specific for this patient's condition?

A. Centromeres
B. Citrullinated peptides
C. Double-stranded DNA
D. Fc portion of human IgG
E. Nuclear basic proteins
F. Phospholipids

Submit

Block Time Remaining: 00:00:45
TUTOR

4 | Feedback | Suspend | End Block

A 47-year-old woman comes to the physician with progressive joint pain and swelling in her hands for the past several months. She also has easy fatigability that has gradually worsened over the same period. Morning activities are especially difficult due to stiffness lasting 1 to 2 hours after waking. Examination shows warmth, swelling, and tenderness involving the proximal interphalangeal joints, metacarpophalangeal joints, and wrists bilaterally. A blood sample is obtained for laboratory analysis. Autoantibodies against which of the following components are most specific for this patient's condition?

- A. Centromeres (2%)
- ✓ B. Citrullinated peptides (52%)
- C. Double-stranded DNA (6%)
- D. Fc portion of human IgG (34%)
- E. Nuclear basic proteins (2%)
- F. Phospholipids (1%)

Omitted
Correct answer
B

52%
Answered correctly

03 secs
Time Spent

01/17/2020
Last Updated

Explanation

Clinical features of rheumatoid arthritis	
	• Pain, swelling & morning stiffness in multiple joints

Clinical features of rheumatoid arthritis	
Clinical presentation	• Pain, swelling & morning stiffness in multiple joints • **Small joints** (PIP, MCP, MTP); spares DIP joints • Systemic symptoms (fever, weight loss, anemia) • **Cervical spine** involvement: subluxation, cord compression
Laboratory/imaging studies	• Positive rheumatoid factor & **anti-CCP antibodies** • C-reactive protein & ESR correlate with disease activity • **X-ray**: soft tissue swelling, joint space narrowing, bony erosions

Anti-CCP = anti–cyclic citrullinated peptide; **DIP** = distal interphalangeal; **ESR** = erythrocyte sedimentation rate; **MCP** = metacarpophalangeal; **MTP** = metatarsophalangeal; **PIP** = proximal interphalangeal.

This patient's symmetric polyarthritis (involving the MCP and PIP joints) with prolonged morning stiffness and associated fatigue is highly suggestive of **rheumatoid arthritis** (RA). The diagnosis is made clinically, but the presence of **anti-cyclic citrullinated peptide (anti-CCP) antibodies** is helpful for confirmation.

Tissue inflammation causes **arginine** residues in proteins such as vimentin to be enzymatically converted into **citrulline** through a process called citrullination. This alters the shape of the proteins, which can then serve as neoantigens that generate an immune response. In RA, the immune response against citrullinated proteins is exaggerated, resulting in high titers of anti-CCP antibodies that are not usually present in other inflammatory conditions. Thus, anti-CCP antibodies have a **high specificity** for RA. Antibodies to citrullinated peptides/proteins are usually measured by enzyme-linked immunosorbent assay (ELISA) using a mixture of CCPs as the antigen.

(Choice A) Anticentromere antibodies are found in the majority of patients with CREST syndrome.

(Choice C) Antibodies to double-stranded DNA (anti-dsDNA) are specific for systemic lupus erythematosus.

(Choice D) Rheumatoid factors are autoantibodies targeting the Fc portion of human IgG that occur in most patients with RA. Their diagnostic utility is limited by their **poor specificity** as they are found in approximately 10% of healthy individuals, in 30% of patients with systemic lupus erythematosus, and in nearly all patients with mixed cryoglobulinemia.

antibodies is helpful for confirmation.

Tissue inflammation causes **arginine** residues in proteins such as vimentin to be enzymatically converted into **citrulline** through a process called citrullination. This alters the shape of the proteins, which can then serve as neoantigens that generate an immune response. In RA, the immune response against citrullinated proteins is exaggerated, resulting in high titers of anti-CCP antibodies that are not usually present in other inflammatory conditions. Thus, anti-CCP antibodies have a **high specificity** for RA. Antibodies to citrullinated peptides/proteins are usually measured by enzyme-linked immunosorbent assay (ELISA) using a mixture of CCPs as the antigen.

(Choice A) Anticentromere antibodies are found in the majority of patients with CREST syndrome.

(Choice C) Antibodies to double-stranded DNA (anti-dsDNA) are specific for systemic lupus erythematosus.

(Choice D) Rheumatoid factors are autoantibodies targeting the Fc portion of human IgG that occur in most patients with RA. Their diagnostic utility is limited by their **poor specificity** as they are found in approximately 10% of healthy individuals, in 30% of patients with systemic lupus erythematosus, and in nearly all patients with mixed cryoglobulinemia.

(Choice E) The presence of antinuclear antibodies (ANA) is a nonspecific finding in many connective tissue disorders. Antinuclear antibodies characteristically occur in IgM form in patients with RA, but they are found less frequently than rheumatoid factors.

(Choice F) Antiphospholipid antibodies are found in patients with systemic lupus erythematosus and antiphospholipid antibody syndrome. Antiphospholipid antibody syndrome causes hypercoagulability, paradoxical partial thromboplastin time (PTT) prolongation, and recurrent miscarriages (spontaneous abortions).

Educational objective:
Rheumatoid arthritis is characterized by symmetric polyarthritis (involving the metacarpophalangeal and proximal interphalangeal joints) with prolonged morning stiffness and associated fatigue. Antibodies to citrullinated peptides/proteins have a high specificity for the condition.

Pathophysiology	Rheumatology/Orthopedics & Sports	Rheumatoid arthritis
Subject	System	Topic

Copyright © UWorld. All rights reserved.

antibodies is helpful for confirmation.

Exhibit Display

CREST syndrome characteristics
Calcinosis
Raynaud phenomenon
Esophageal dysmotility
Sclerodactyly
Telangiectasias

©UWorld

Zoom In | Zoom Out | Reset | Add To New Card | Existing Card

Settings

1
2
3
4
5
6
7
8
9
10
11
12
13
14
15
16
17
18
19
20

Item 13 of 20
Question Id: 640

Mark | Previous | Next | Full Screen | Tutorial | Lab Values | Notes | Calculator | Reverse Color | Text Zoom | Settings

A group of investigators is studying the process of bone remodeling in response to steroid hormones. Twenty adult female rats are randomly divided into 2 groups, with one group undergoing bilateral oophorectomy and the other undergoing sham laparotomy to serve as a control group. Eight weeks after the surgery, bone samples are obtained from all animals. Immunohistochemical evaluation shows overexpression of receptor activator of nuclear factor kappa B (RANK) on the surface of certain bone cells in the oophorectomized animals. Which of the following is the most likely effect of the observed finding?

A. Decreased bone mineralization
B. Decreased osteocyte apoptosis
C. Decreased osteoid formation
D. Increased bone resorption
E. Increased osteoprotegerin levels

Submit

Block Time Remaining: 00:00:47
TUTOR

2 | Feedback | Suspend | End Block

A group of investigators is studying the process of bone remodeling in response to steroid hormones. Twenty adult female rats are randomly divided into 2 groups, with one group undergoing bilateral oophorectomy and the other undergoing sham laparotomy to serve as a control group. Eight weeks after the surgery, bone samples are obtained from all animals. Immunohistochemical evaluation shows overexpression of receptor activator of nuclear factor kappa B (RANK) on the surface of certain bone cells in the oophorectomized animals. Which of the following is the most likely effect of the observed finding?

- A. Decreased bone mineralization (4%)
- B. Decreased osteocyte apoptosis (3%)
- C. Decreased osteoid formation (2%)
- ✓ D. Increased bone resorption (87%)
- E. Increased osteoprotegerin levels (2%)

Omitted
Correct answer
D

87%
Answered correctly

02 secs
Time Spent

02/15/2020
Last Updated

Explanation

Osteoclast differentiation

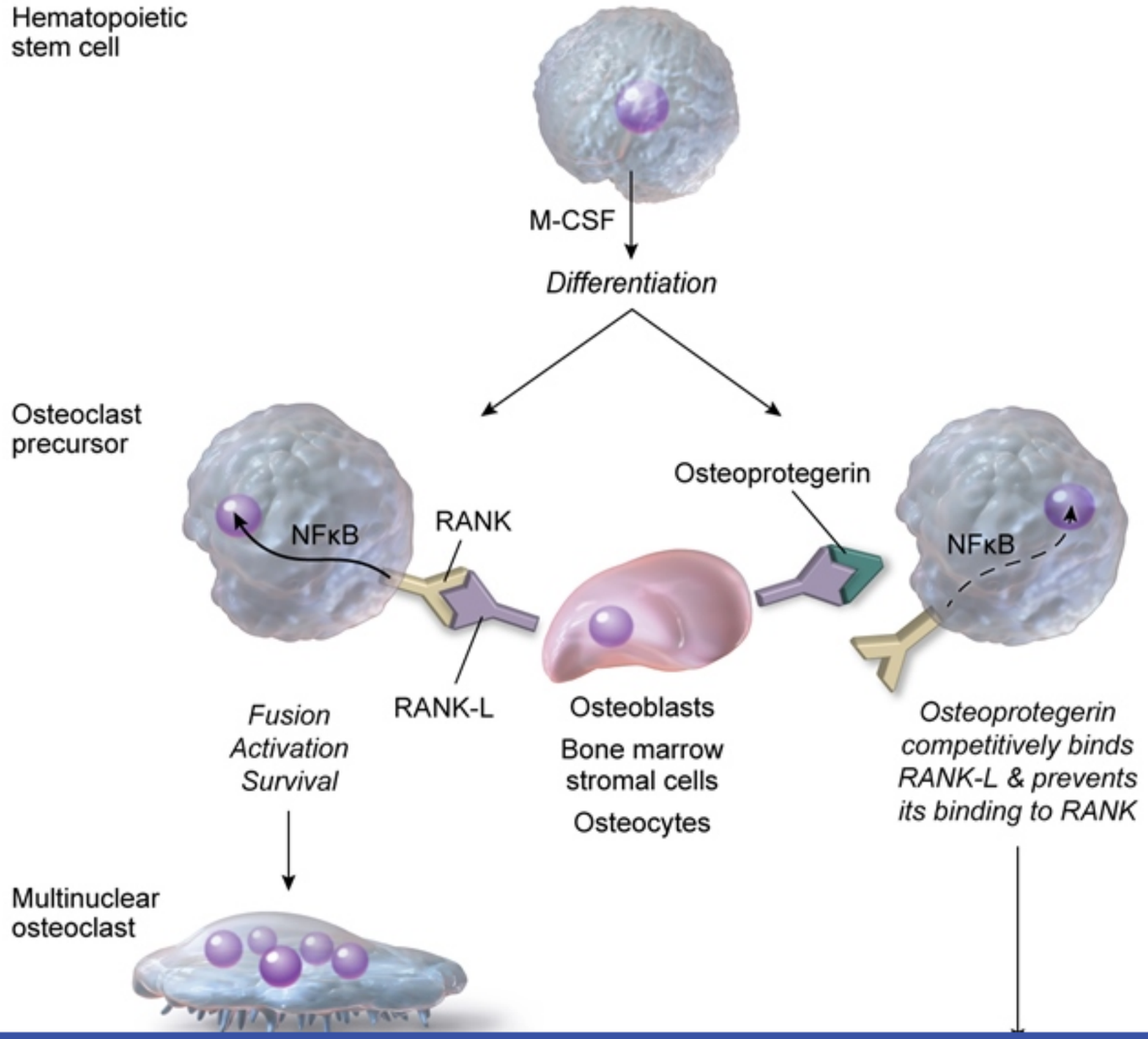

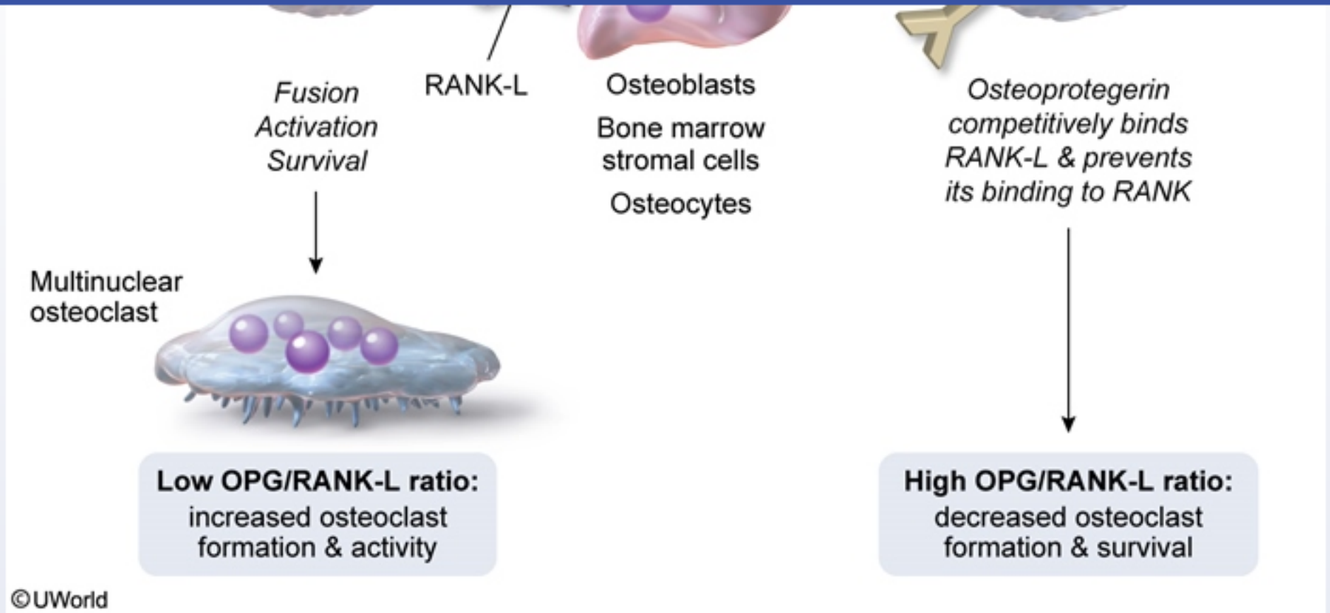

The 2 most important factors in osteoclast differentiation are macrophage colony-stimulating factor (**M-CSF**) and receptor activator of nuclear factor kappa B ligand (**RANK-L**), which stimulate the development of mature, multinucleated osteoclasts. The interaction of RANK-L with RANK (receptor) is blocked by **osteoprotegerin** (OPG), which acts as a decoy receptor. By binding RANK-L, OPG reduces the differentiation and survival of osteoclasts, resulting in decreased bone resorption and increased bone density. Bone turnover is therefore regulated by the **ratio of OPG to RANK-L**; bone turnover increases when OPG is low and RANK-L is high.

Estrogen maintains bone mass in premenopausal women by inducing the production of OPG by osteoblasts and stromal cells. It also decreases the expression of RANK on osteoclast precursors. By contrast, the **loss of estrogen effect** (eg, menopause, oophorectomy) increases the expression of RANK-L and decreases production of OPG **(Choice E)**. The decreased OPG to RANK-L ratio leads to **increased osteoclast activity** and bone resorption. Denosumab is a monoclonal antibody used in the treatment of postmenopausal osteoporosis. It works in a manner similar to OPG by binding RANK-L and blocking its interaction with RANK.

(Choices A and C) RANK is not present on osteoblasts, so the decreased OPG to RANK-L ratio seen following oophorectomy does not affect bone mineralization or osteoid formation.

factor kappa B ligand (**RANK-L**), which stimulate the development of mature, multinucleated osteoclasts. The interaction of RANK-L with RANK (receptor) is blocked by **osteoprotegerin** (OPG), which acts as a decoy receptor. By binding RANK-L, OPG reduces the differentiation and survival of osteoclasts, resulting in decreased bone resorption and increased bone density. Bone turnover is therefore regulated by the **ratio of OPG to RANK-L**; bone turnover increases when OPG is low and RANK-L is high.

Estrogen maintains bone mass in premenopausal women by inducing the production of OPG by osteoblasts and stromal cells. It also decreases the expression of RANK on osteoclast precursors. By contrast, the **loss of estrogen effect** (eg, menopause, oophorectomy) increases the expression of RANK-L and decreases production of OPG **(Choice E)**. The decreased OPG to RANK-L ratio leads to **increased osteoclast activity** and bone resorption. Denosumab is a monoclonal antibody used in the treatment of postmenopausal osteoporosis. It works in a manner similar to OPG by binding RANK-L and blocking its interaction with RANK.

(Choices A and C) RANK is not present on osteoblasts, so the decreased OPG to RANK-L ratio seen following oophorectomy does not affect bone mineralization or osteoid formation.

(Choice B) Osteocytes are derived from osteoblasts. Estrogen reduces osteoblast and osteocyte apoptosis through activation of extracellular signal–regulated kinases rather than effects on RANK/RANK-L.

Educational objective:
The receptor activator of nuclear factor kappa B (RANK)/RANK ligand (RANK-L) interaction is essential for the formation and differentiation of osteoclasts. Osteoprotegerin blocks binding of RANK-L to RANK and reduces formation of mature osteoclasts. Low estrogen states cause osteoporosis by decreasing osteoprotegerin production, increasing RANK-L production, and increasing RANK expression in osteoclast precursors.

References

- Prevention and treatment of postmenopausal osteoporosis.

Pathophysiology	Rheumatology/Orthopedics & Sports	Osteoporosis
Subject	System	Topic

Copyright © UWorld. All rights reserved.

A 54-year-old man is admitted to the hospital following a high-speed motor vehicle accident. He is found to have right leg long bone fractures requiring open reduction/internal fixation. After the patient is stabilized, he is transferred to a skilled nursing facility for an extended rehabilitation period. During his stay at the facility, his right leg is immobilized for several weeks. The patient's management is complicated by decreased nutritional intake due to side effects from opioid pain medications. Measurement of his thigh following removal of casting materials finds a 2-centimeter decrease in diameter during the time of immobilization. This change in body measurement is due to a pathologic process similar to that seen in which of the following?

A. Adrenal glands during prolonged glucocorticoid therapy

B. Endometrial tissue during estrogen replacement therapy

C. Esophageal mucosa upon repeated acid exposure

D. Heart muscle during long-standing hypertension

E. Lung tissue after prolonged tobacco smoke exposure

Submit

A 54-year-old man is admitted to the hospital following a high-speed motor vehicle accident. He is found to have right leg long bone fractures requiring open reduction/internal fixation. After the patient is stabilized, he is transferred to a skilled nursing facility for an extended rehabilitation period. During his stay at the facility, his right leg is immobilized for several weeks. The patient's management is complicated by decreased nutritional intake due to side effects from opioid pain medications. Measurement of his thigh following removal of casting materials finds a 2-centimeter decrease in diameter during the time of immobilization. This change in body measurement is due to a pathologic process similar to that seen in which of the following?

- ✓ A. Adrenal glands during prolonged glucocorticoid therapy (92%)
- B. Endometrial tissue during estrogen replacement therapy (2%)
- C. Esophageal mucosa upon repeated acid exposure (0%)
- D. Heart muscle during long-standing hypertension (2%)
- E. Lung tissue after prolonged tobacco smoke exposure (1%)

Omitted
Correct answer
A

92%
Answered correctly

02 secs
Time Spent

01/20/2020
Last Updated

Explanation

This patient experienced decreased physical workload when his leg was immobilized. As a result, the skeletal muscle fibers in his leg decreased in size, leading to **disuse atrophy**. Atrophy is tissue loss due to **cellular death** or **reduced cell size**. It may be physiologic (eg, atrophy of Wolffian ducts in the female fetus, atrophy of maternal uterus following childbirth) or pathologic. Pathologic atrophy can be due to lack of use, loss of hormonal or neurologic stimulation (denervation atrophy), impaired circulation, mechanical compression, aging, or nutritional insufficiency.

This patient experienced decreased physical workload when his leg was immobilized. As a result, the skeletal muscle fibers in his leg decreased in size, leading to **disuse atrophy**. Atrophy is tissue loss due to **cellular death** or **reduced cell size**. It may be physiologic (eg, atrophy of Wolffian ducts in the female fetus, atrophy of maternal uterus following childbirth) or pathologic. Pathologic atrophy can be due to lack of use, loss of hormonal or neurologic stimulation (denervation atrophy), impaired circulation, mechanical compression, aging, or nutritional insufficiency. Pathologic atrophy may be local or generalized. On a cellular level, atrophy is seen as a reduction in mitochondria and rough endoplasmic reticulum. Muscular atrophy is characterized by decreased protein synthesis and loss of myofibrils. In prolonged atrophic states, **apoptosis** can lead to reduced cellular numbers.

Pathologic atrophy is also seen in the adrenal cortex during prolonged glucocorticoid use due to suppression of ACTH release. This can lead to acute adrenal insufficiency if the exogenous glucocorticoid therapy is abruptly discontinued.

(Choice B) After menopause, falling estrogen levels can lead to atrophy of the breasts, endometrium, and vaginal mucosa. Conversely, estrogen replacement in these patients can cause endometrial hyperplasia unless combined with progesterone therapy.

(Choice C) In chronic gastroesophageal reflux, esophageal mucosa subjected to repeated acid exposure may undergo metaplasia. Squamous epithelium is replaced by columnar epithelium in a condition known as Barrett esophagus.

(Choice D) Heart muscle subjected to long-standing hypertension is prone to developing hypertrophy, not atrophy.

(Choice E) Prolonged exposure to tobacco smoke can induce metaplasia in the epithelium of the lung. Columnar epithelium may be replaced by squamous epithelium (squamous metaplasia) with an associated risk of squamous cell carcinoma.

Educational objective:
Pathologic atrophy can be caused by decreased physical workload, loss of innervation, decreased blood supply, inadequate nutrition, absent endocrine stimulation, aging, or mechanical pressure.

References

- Disuse-induced muscle wasting.

Pathophysiology Rheumatology/Orthopedics & Sports Atrophy

Settings

1
2
3
4
5
6
7
8
9
10
11
12
13
14
15
16
17
18
19
20

Item 15 of 20
Question Id: 743

Mark | Previous | Next | Full Screen | Tutorial | Lab Values | Notes | Calculator | Reverse Color | Text Zoom | Settings

A 34-year-old man comes to the physician due to painful urination. Physical examination shows a watery penile discharge. Urethral swabs obtained from the patient are negative for gonococcal infection. He is treated appropriately and his symptoms resolve. Two weeks later, he develops acute conjunctivitis, right knee pain, and vesicular rash on his palms and soles. This patient's condition is most likely associated with which of the following?

A. Esophageal dysmotility
B. Hyperparathyroidism
C. Polymyositis
D. Sacroiliitis
E. Tabes dorsalis

Submit

Block Time Remaining: 00:00:51
TUTOR

1 | Feedback | Suspend | End Block

A 34-year-old man comes to the physician due to painful urination. Physical examination shows a watery penile discharge. Urethral swabs obtained from the patient are negative for gonococcal infection. He is treated appropriately and his symptoms resolve. Two weeks later, he develops acute conjunctivitis, right knee pain, and vesicular rash on his palms and soles. This patient's condition is most likely associated with which of the following?

- A. Esophageal dysmotility (3%)
- B. Hyperparathyroidism (0%)
- C. Polymyositis (11%)
- ✓ D. Sacroiliitis (48%)
- E. Tabes dorsalis (35%)

Omitted
Correct answer
D

48%
Answered correctly

02 secs
Time Spent

06/27/2020
Last Updated

Explanation

Reactive arthritis	
Preceding infection	• **Genitourinary infection:** *Chlamydia trachomatis* • **Enteritis:** *Salmonella, Shigella, Yersinia, Campylobacter, Clostridioides* (formerly *Clostridium*) *difficile*

Reactive arthritis	
Preceding infection	• **Genitourinary infection:** *Chlamydia trachomatis* • **Enteritis:** *Salmonella, Shigella, Yersinia, Campylobacter, Clostridioides* (formerly *Clostridium*) *difficile*
Musculoskeletal	• Asymmetric oligo**arthritis** • Enthesitis • Dactylitis
Extraarticular symptoms	• Ocular: **conjunctivitis**, anterior uveitis • Genital: **urethritis**, cervicitis, prostatitis • Dermal: keratoderma blennorrhagicum, circinate balanitis • Oral ulcers

Urethritis, conjunctivitis, and **mono- or oligoarticular arthritis** constitute the classic triad of **reactive arthritis** (ReA). This seronegative (rheumatoid factor-negative) spondyloarthropathy most commonly affects patients age 20-40 and is associated with **HLA-B27**. Symptoms generally manifest 1-4 weeks following a primary infection causing urethritis or enteritis and are caused by an autoimmune reaction initiated by the infecting pathogen. Skin findings include keratoderma blennorrhagicum (hyperkeratotic vesicles on the palms and soles) and circinate balanitis (serpiginous annular dermatitis of the glans penis). Axial involvement, including **sacroiliitis**, may occur in about 20% of cases.

(Choice A) Esophageal dysmotility is a classic finding in scleroderma although it can occur in other conditions.

(Choice B) Hyperparathyroidism may occur in the setting of multiple endocrine neoplasia.

(Choice C) Polymyositis may occur in the setting of dermatomyositis or as a separate entity.

(Choice E) Tabes dorsalis is a manifestation of tertiary syphilis. Secondary syphilis causes maculopapular or pustular (but not vesicular) rash that can involve the palms and soles; it is generally associated with polyarthritis (mono-arthritis is very rare).

Extraarticular symptoms	• Ocular: **conjunctivitis**, anterior uveitis • Genital: **urethritis**, cervicitis, prostatitis • Dermal: keratoderma blennorrhagicum, circinate balanitis • Oral ulcers

Urethritis, conjunctivitis, and **mono- or oligoarticular arthritis** constitute the classic triad of **reactive arthritis** (ReA). This seronegative (rheumatoid factor-negative) spondyloarthropathy most commonly affects patients age 20-40 and is associated with **HLA-B27**. Symptoms generally manifest 1-4 weeks following a primary infection causing urethritis or enteritis and are caused by an autoimmune reaction initiated by the infecting pathogen. Skin findings include keratoderma blennorrhagicum (hyperkeratotic vesicles on the palms and soles) and circinate balanitis (serpiginous annular dermatitis of the glans penis). Axial involvement, including **sacroiliitis**, may occur in about 20% of cases.

(Choice A) Esophageal dysmotility is a classic finding in scleroderma although it can occur in other conditions.

(Choice B) Hyperparathyroidism may occur in the setting of multiple endocrine neoplasia.

(Choice C) Polymyositis may occur in the setting of dermatomyositis or as a separate entity.

(Choice E) Tabes dorsalis is a manifestation of tertiary syphilis. Secondary syphilis causes maculopapular or pustular (but not vesicular) rash that can involve the palms and soles; it is generally associated with polyarthritis (mono-arthritis is very rare).

Educational objective:
The classic triad of reactive arthritis is nongonococcal urethritis, conjunctivitis, and arthritis. It is an HLA-B27-associated arthropathy that occurs within several weeks following a genitourinary or enteric infection. It belongs to the group of seronegative spondyloarthropathies (including ankylosing spondylitis) and can cause sacroiliitis in about 20% of cases.

Pathophysiology	Rheumatology/Orthopedics & Sports	Reactive arthritis
Subject	System	Topic

Copyright © UWorld. All rights reserved.

A 55-year-old man comes to the office for evaluation of chronic muscle weakness. Over the past several months, he has had increasing difficulty walking up stairs and lately has had trouble removing objects out of the overhead cabinets in his kitchen. Temperature is 36.7 C (98 F), blood pressure is 125/80 mm Hg, and pulse is 78/min. On examination, the patient has symmetric proximal muscle weakness and mild muscle tenderness. There is no rash. Muscle biopsy reveals an endomysial mononuclear infiltrate and patchy muscle fiber necrosis. An autoantibody directed against which of the following antigens is most likely to be seen in this patient?

A. Acetylcholine receptor
B. Cardiolipin
C. Desmoglein
D. Mitochondria
E. Presynaptic calcium channel
F. tRNA synthetase
G. Smooth muscle

Submit

A 55-year-old man comes to the office for evaluation of chronic muscle weakness. Over the past several months, he has had increasing difficulty walking up stairs and lately has had trouble removing objects out of the overhead cabinets in his kitchen. Temperature is 36.7 C (98 F), blood pressure is 125/80 mm Hg, and pulse is 78/min. On examination, the patient has symmetric proximal muscle weakness and mild muscle tenderness. There is no rash. Muscle biopsy reveals an endomysial mononuclear infiltrate and patchy muscle fiber necrosis. An autoantibody directed against which of the following antigens is most likely to be seen in this patient?

- A. Acetylcholine receptor (8%)
- B. Cardiolipin (4%)
- C. Desmoglein (16%)
- D. Mitochondria (13%)
- E. Presynaptic calcium channel (10%)
- ✓ F. tRNA synthetase (38%)
- G. Smooth muscle (7%)

Omitted
Correct answer
F

38%
Answered correctly

02 secs
Time Spent

03/01/2020
Last Updated

Explanation

Polymyositis

Polymyositis	
Clinical presentation	• Symmetrical proximal **muscle weakness** • Increasing difficulty climbing stairs, getting up from a chair, carrying heavy objects
Pathologic features	• **Elevated muscle enzymes** (CK, aldolase) • Autoantibodies (ANA, anti–Jo-1) • **Biopsy**: Endomysial mononuclear infiltrate, patchy necrosis
Associated complications	• Interstitial lung disease • Myocarditis

ANA = antinuclear antibodies; **CK** = creatine kinase.

Polymyositis is an inflammatory myopathy that typically presents in middle age with an insidious onset of symmetric **proximal muscle weakness** affecting the upper and lower extremities without significant pain. Dermatomyositis is a similar disorder associated with characteristic skin findings. Both polymyositis and dermatomyositis may occur independently or as a paraneoplastic manifestation of an underlying malignancy (especially **adenocarcinoma**).

Muscle enzyme (eg, creatine kinase, aldolase) levels in inflammatory myopathies are invariably elevated. Autoantibodies, especially antinuclear antibodies, are also present in most cases; anti–histidyl-**tRNA synthetase (anti–Jo-1)** antibodies are less sensitive but more specific for dermatomyositis and polymyositis. A biopsy can differentiate polymyositis from dermatomyositis, which typically shows an **endomysial inflammation** without prominent vascular involvement in a scattered or patchy distribution (in contrast, dermatomyositis causes *perifascicular inflammation* in a segmental pattern without vasculopathy).

(Choices A and E) Acetylcholine receptor–binding antibodies occur in myasthenia gravis, which is characterized by episodic weakness that initially affects the ocular/bulbar musculature and worsens with repetition. Antibodies to voltage-gated calcium channels cause Lambert-Eaton

antibodies, are also present in most cases; anti–histidyl-**tRNA synthetase (anti–Jo-1)** antibodies are less sensitive but more specific for dermatomyositis and polymyositis. A biopsy can differentiate polymyositis from dermatomyositis, which typically shows an **endomysial inflammation** without prominent vascular involvement in a scattered or patchy distribution (in contrast, dermatomyositis causes *perifascicular inflammation* in a segmental pattern without vasculopathy).

(Choices A and E) Acetylcholine receptor–binding antibodies occur in myasthenia gravis, which is characterized by episodic weakness that initially affects the ocular/bulbar musculature and worsens with repetition. Antibodies to voltage-gated calcium channels cause Lambert-Eaton myasthenic syndrome (proximal muscle weakness that improves with isometric contraction), which is often associated with small cell lung cancer. Muscle biopsy in these conditions is normal.

(Choice B) Anticardiolipin antibodies are typically seen in antiphospholipid antibody syndrome, which is characterized by recurrent vascular thrombosis and/or pregnancy loss. This syndrome is associated with systemic lupus erythematosus, although it may occur independently.

(Choice C) Autoantibodies to desmoglein 1 and 3 are seen in patients with pemphigus vulgaris, which is characterized by skin blistering and desquamation.

(Choices D and G) Antimitochondrial antibodies are seen in patients with primary biliary cholangitis, which presents with cholestatic symptoms (eg, pruritus, jaundice, steatorrhea) and abnormal hepatic enzyme levels. Anti–smooth muscle antibodies are seen in autoimmune hepatitis, which most commonly presents as chronic progressive hepatitis in middle-aged women.

Educational objective:
Polymyositis and dermatomyositis are characterized by symmetric proximal muscle weakness and are associated with antinuclear and anti–tRNA synthetase (anti-Jo-1) autoantibodies. Biopsy in polymyositis shows patchy endomysial inflammatory infiltrate (ie, direct invasion of individual muscle fibers), whereas dermatomyositis causes perifascicular inflammation (ie, localized around blood vessels and the septa between muscle fascicles).

References

- An overview of polymyositis and dermatomyositis.

Pathophysiology Rheumatology/Orthopedics & Sports Polymyositis and dermatomyositis

Settings

1
2
3
4
5
6
7
8
9
10
11
12
13
14
15
16
17
18
19
20

Item 16 of 20
Question Id: 11646

Mark | Previous | Next | Full Screen | Tutorial | Lab Values | Notes | Calculator | Reverse Color | Text Zoom | Settings

features • **Biopsy**: Endomysial mononuclear infiltrate,

Exhibit Display

Dermatomyositis Gottron's papules

Zoom In | Zoom Out | Reset | Add To New Card | Existing Card

(Choices D and G) Antimitochondrial antibodies are seen in patients with primary biliary cholangitis, which presents with cholestatic symptoms

Block Time Remaining: 00:00:55
TUTOR

4 | Feedback | Suspend | End Block

Settings

1
2
3
4
5
6
7
8
9
10
11
12
13
14
15
16
17
18
19
20

Item 16 of 20
Question Id: 11646

Mark | Previous | Next | Full Screen | Tutorial | Lab Values | Notes | Calculator | Reverse Color | Text Zoom | Settings

features • **Biopsy**: Endomysial mononuclear infiltrate,

Exhibit Display

Dermatomyositis Gottron's papules

Zoom In | Zoom Out | Reset | Add To New Card | Existing Card

(Choices D and G) Antimitochondrial antibodies are seen in patients with primary biliary cholangitis, which presents with cholestatic symptoms

Block Time Remaining: 00:00:55
TUTOR

4 | Feedback | Suspend | End Block

A 17-year-old girl is brought to the office for evaluation of a right wrist mass. She noticed swelling on the top of her wrist approximately 3 months ago but said that it did not bother her until she was teased about it in school. She has no other concerns. Examination shows a nontender, rounded mass on the dorsal wrist that transilluminates with a penlight. An image of the mass is shown below:

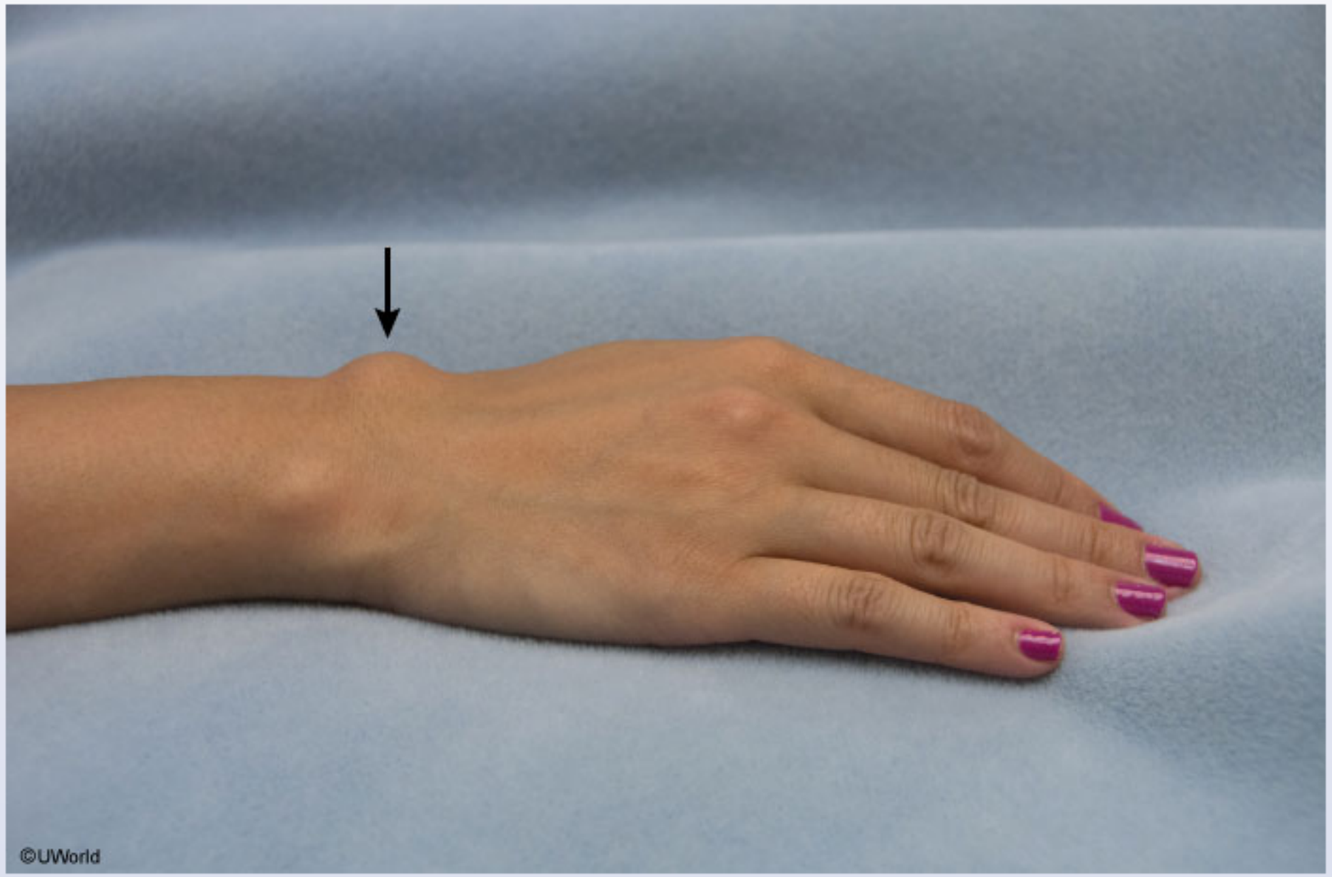

Which of the following is the most likely underlying etiology?

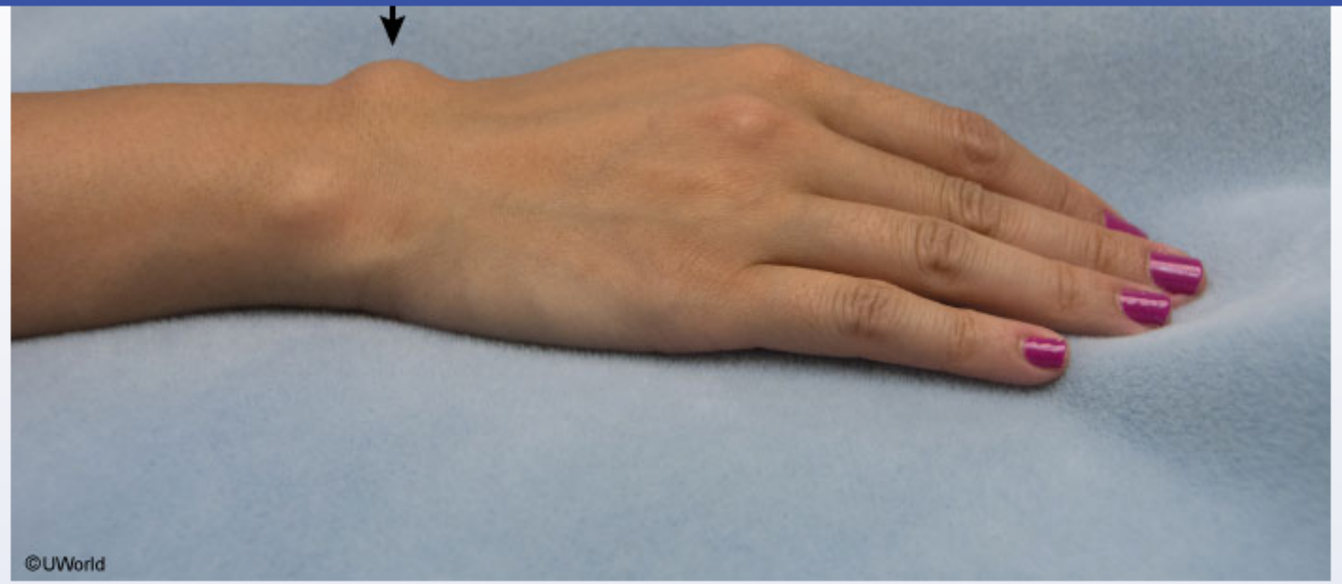

Which of the following is the most likely underlying etiology?

- A. Benign proliferation of fat cells
- B. Degeneration of periarticular tissue
- C. Immune-mediated joint destruction
- D. Malignant transformation of synovial tissue
- E. Uric acid crystal deposition

Submit

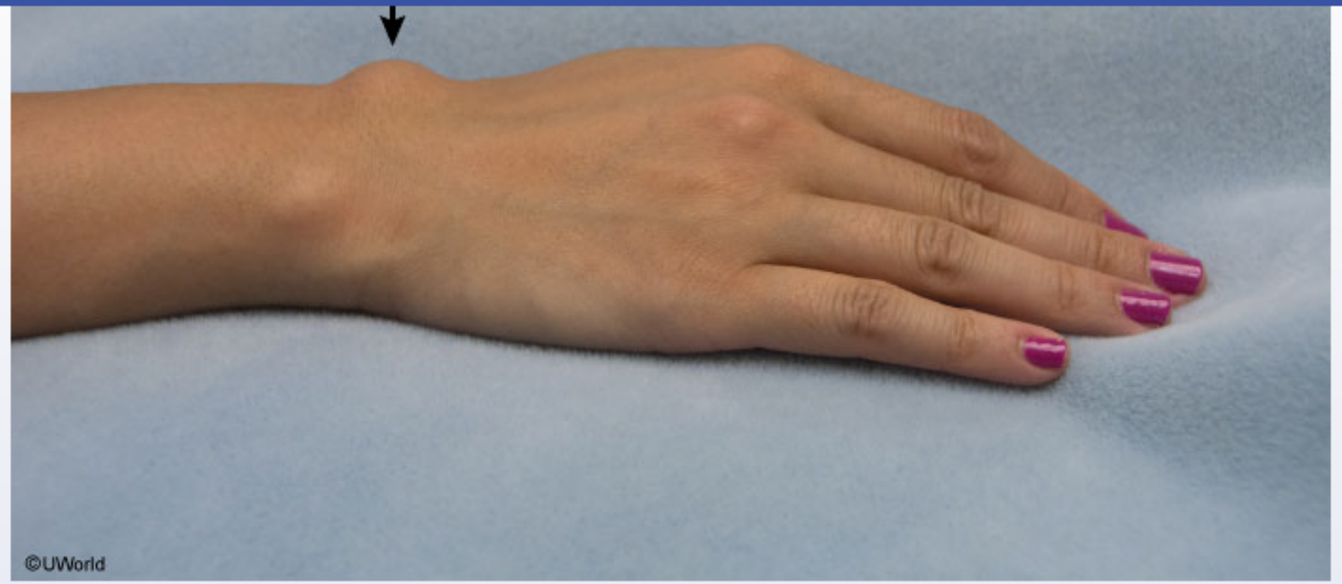

Which of the following is the most likely underlying etiology?

- A. Benign proliferation of fat cells (57%)
- ✓ B. Degeneration of periarticular tissue (30%)
- C. Immune-mediated joint destruction (2%)
- D. Malignant transformation of synovial tissue (9%)
- E. Uric acid crystal deposition (1%)

Omitted
Correct answer

30%
Answered correctly

07 secs
Time Spent

03/09/2020
Last Updated

Ganglion cyst	
Pathophysiology	• Mucoid degeneration of periarticular tissue • Mucinous fluid collects via a 1-way valve mechanism
Presentation	• Usually painless but can cause mild aching or compressive symptoms • Smooth, rubbery, round structure that overlies a joint or tendon & transilluminates
Management	• Usually resolves spontaneously

This patient has a **ganglion cyst**, a benign, fluid-filled mass that overlies a joint or tendon. Ganglion cysts occur most commonly on the dorsal wrist; other common sites include the volar wrist, digits, and feet. They are thought to be due to **mucoid degeneration of periarticular tissue**, leading to outpouching of the connective tissue. Mucinous fluid collects via a 1-way valve mechanism, possibly due to repetitive joint movements, resulting in slow growth of the cyst.

Ganglion cysts are usually **painless**, and most patients seek medical attention because of cosmetic concerns or fear of malignancy. However, some patients may experience mild aching, and significant compression can occasionally result in paresthesia or weakness. Physical examination reveals a **smooth**, rubbery, **round structure** that overlies a joint or tendon and **transilluminates** with a penlight. Most ganglion cysts **resolve spontaneously** without intervention.

(Choice A) Lipomas are benign neoplasms caused by the proliferation of fat cells. Although they can occur on the wrist, they most commonly present on the trunk or proximal arms. Lipomas do not transilluminate.

(Choice C) Rheumatoid arthritis (RA) is characterized by immune-mediated joint destruction. It can be associated with rheumatoid nodules, which present as nontender subcutaneous nodules over pressure points (eg, olecranon process). However, rheumatoid nodules do not transilluminate, and patients with RA typically have symmetric joint swelling and pain in the small joints of the hands and wrists, as well as characteristic joint deformities (eg, ulnar deviation).

(Choice D) Synovial sarcoma occurs from the malignant transformation of synovial tissue and can cause isolated swelling along the tendons. However, it does not transilluminate.

This patient has a **ganglion cyst**, a benign, fluid-filled mass that overlies a joint or tendon. Ganglion cysts occur most commonly on the dorsal wrist; other common sites include the volar wrist, digits, and feet. They are thought to be due to **mucoid degeneration of periarticular tissue**, leading to outpouching of the connective tissue. Mucinous fluid collects via a 1-way valve mechanism, possibly due to repetitive joint movements, resulting in slow growth of the cyst.

Ganglion cysts are usually **painless**, and most patients seek medical attention because of cosmetic concerns or fear of malignancy. However, some patients may experience mild aching, and significant compression can occasionally result in paresthesia or weakness. Physical examination reveals a **smooth**, rubbery, **round structure** that overlies a joint or tendon and **transilluminates** with a penlight. Most ganglion cysts **resolve spontaneously** without intervention.

(Choice A) Lipomas are benign neoplasms caused by the proliferation of fat cells. Although they can occur on the wrist, they most commonly present on the trunk or proximal arms. Lipomas do not transilluminate.

(Choice C) Rheumatoid arthritis (RA) is characterized by immune-mediated joint destruction. It can be associated with rheumatoid nodules, which present as nontender subcutaneous nodules over pressure points (eg, olecranon process). However, rheumatoid nodules do not transilluminate, and patients with RA typically have symmetric joint swelling and pain in the small joints of the hands and wrists, as well as characteristic joint deformities (eg, ulnar deviation).

(Choice D) Synovial sarcoma occurs from the malignant transformation of synovial tissue and can cause isolated swelling along the tendons. However, it does not transilluminate.

(Choice E) Tophi occur from chronic uric acid deposition and present with firm, nontender subcutaneous nodules that are often yellow tinged; they do not transilluminate. In addition, patients usually have a history of recurrent gout flares (ie, exquisitely painful, swollen, erythematous joint).

Educational objective:
Ganglion cysts are benign, fluid-filled masses that occur due to mucoid degeneration of periarticular tissue. They present as painless, smooth, rubbery, round structures that overlie joints (eg, wrist) or tendons and transilluminate with a penlight. Most resolve spontaneously without intervention.

Pathophysiology Rheumatology/Orthopedics & Sports Ganglion cyst

Settings

1
2
3
4
5
6
7
8
9
10
11
12
13
14
15
16
17
18
19
20

Item 17 of 20
Question Id: 18661

Mark | Previous | Next | Full Screen | Tutorial | Lab Values | Notes | Calculator | Reverse Color | Text Zoom | Settings

This patient has a **ganglion cyst**, a benign, fluid-filled mass that overlies a joint or tendon. Ganglion cysts occur most commonly on the dorsal

Exhibit Display

Zoom In | Zoom Out | Reset | Add To Flash Card

Pathophysiology | Rheumatology/Orthopedics & Sports | Ganglion cyst

Block Time Remaining: 00:01:02
TUTOR

0 | Feedback | Suspend | End Block

Settings

1
2
3
4
5
6
7
8
9
10
11
12
13
14
15
16
17
18
19
20

Item 17 of 20
Question Id: 18661

Mark | Previous | Next | Full Screen | Tutorial | Lab Values | Notes | Calculator | Reverse Color | Text Zoom | Settings

This patient has a **ganglion cyst**, a benign, fluid-filled mass that overlies a joint or tendon. Ganglion cysts occur most commonly on the dorsal

Exhibit Display

Zoom In | Zoom Out | Reset | Add To Flash Card

Pathophysiology | Rheumatology/Orthopedics & Sports | Ganglion cyst

Block Time Remaining: 00:01:02
TUTOR

0 | Feedback | Suspend | End Block

Settings

1
2
3
4
5
6
7
8
9
10
11
12
13
14
15
16
17
18
19
20

Item 17 of 20
Question Id: 18661

Mark | Previous | Next | Full Screen | Tutorial | Lab Values | Notes | Calculator | Reverse Color | Text Zoom | Settings

This patient has a **ganglion cyst**, a benign, fluid-filled mass that overlies a joint or tendon. Ganglion cysts occur most commonly on the dorsal

Exhibit Display

Zoom In | Zoom Out | Reset | Add To Flash Card

Pathophysiology | Rheumatology/Orthopedics & Sports | Ganglion cyst

Block Time Remaining: 00:01:02
TUTOR

0 | Feedback | Suspend | End Block

This patient has a **ganglion cyst**, a benign, fluid-filled mass that overlies a joint or tendon. Ganglion cysts occur most commonly on the dorsal

Exhibit Display

Gouty tophi

Zoom In Zoom Out Reset Add To Flash Card

Pathophysiology Rheumatology/Orthopedics & Sports Ganglion cyst

A 48-year-old previously healthy woman comes to the office due to progressively worsening muscle weakness for the past 2 months. The patient has difficulty with activities such as climbing stairs, getting up from chairs, and placing dishes in overhead cabinets. She also reports a 4.5-kg (10-lb) unintentional weight loss and occasional abdominal discomfort over the same interval. Physical examination shows weakness of the shoulder and hip girdle muscles. Other examination findings are shown in the image below.

Settings

1
2
3
4
5
6
7
8
9
10
11
12
13
14
15
16
17
18
19
20

Item 18 of 20
Question Id: 11805

Mark | Previous | Next | Full Screen | Tutorial | Lab Values | Notes | Calculator | Reverse Color | Text Zoom | Settings

Block Time Remaining: 00:01:06
TUTOR

5 | Feedback | Suspend | End Block

Further evaluation of this patient is most likely to reveal which of the following associated conditions?

A. Chronic hepatitis C infection

B. Ovarian adenocarcinoma

C. Primary biliary cholangitis

D. *Tropheryma whippelii* infection

E. Type 2 diabetes mellitus

Submit

Further evaluation of this patient is most likely to reveal which of the following associated conditions?

A. Chronic hepatitis C infection (10%)

✓ B. Ovarian adenocarcinoma (40%)

C. Primary biliary cholangitis (34%)

D. *Tropheryma whippelii* infection (10%)

E. Type 2 diabetes mellitus (4%)

Omitted
Correct answer

40%
Answered correctly

08 secs
Time Spent

03/01/2020
Last Updated

Explanation

Dermatomyositis is a systemic autoimmune disease characterized by proximal muscle weakness resembling polymyositis, with additional inflammatory features involving the skin. Specific skin findings include the heliotrope rash in the periorbital area and cheeks and **Gottron papules**, which are raised erythematous plaques over the joints and bony prominences of the hands (as seen in this patient). Muscle biopsy is diagnostic and shows mononuclear **perifascicular inflammation** and atrophy (ie, occurring along the periphery of the fascicles).

Dermatomyositis may occur alone or as a **paraneoplastic syndrome** of an underlying malignancy, most commonly due to underlying **adenocarcinoma** (eg, ovary, lung, pancreas). Symptoms may precede the diagnosis of malignancy but often parallel the course of the cancer.

(Choice A) Hepatitis C infection is associated with porphyria cutanea tarda, which presents with skin fragility and a blistering rash in sun-exposed areas, and mixed cryoglobulinemic vasculitis, which presents with nonblanching palpable purpura. Muscle symptoms are not typical.

(Choice C) Primary biliary cholangitis (previously primary biliary cirrhosis) is an autoimmune liver disease that can present with cholestasis, malabsorption, pruritus, and jaundice. Although the risk of this condition is increased in patients with autoimmune disease (eg, CREST syndrome, Sjögren syndrome), the association with dermatomyositis is not common.

(Choice D) *Tropheryma whippelii* infection (Whipple disease) typically presents with arthritis, diarrhea, and fever. Patients may develop hyperpigmentation, but skin and muscle symptoms are otherwise not prominent.

(Choice E) Type 2 diabetes is due to insulin resistance, which may also cause acanthosis nigricans, a condition characterized by velvety patches of brownish discoloration affecting the neck and skinfolds.

Educational objective:
Dermatomyositis is characterized by proximal muscle weakness resembling polymyositis, with additional inflammatory features involving the skin (heliotrope rash, Gottron papules). Both dermatomyositis and polymyositis may occur alone or as a paraneoplastic syndrome associated with an underlying adenocarcinoma (eg, ovary, lung, pancreas).

References

- Dermatomyositis as the first manifestation of a lung tumor.
- Malignancy in myositis.

Settings

1
2
3
4
5
6
7
8
9
10
11
12
13
14
15
16
17
18
19
20

Item 18 of 20
Question Id: 11805

Mark | Previous | Next | Full Screen | Tutorial | Lab Values | Notes | Calculator | Reverse Color | Text Zoom | Settings

Correct answer | Answered correctly | Time Spent | Last Updated

Exhibit Display

Zoom In | Zoom Out | Reset | Add To New Card | Existing Card

underlying adenocarcinoma (eg, ovary, lung, pancreas).

Block Time Remaining: 00:01:10
TUTOR

5 | Feedback | Suspend | End Block

Settings

1
2
3
4
5
6
7
8
9
10
11
12
13
14
15
16
17
18
19
20

Item 18 of 20
Question Id: 11805

Mark | Previous | Next | Full Screen | Tutorial | Lab Values | Notes | Calculator | Reverse Color | Text Zoom | Settings

Correct answer | Answered correctly | Time Spent | Last Updated

Exhibit Display

Zoom In | Zoom Out | Reset | Add To New Card | Existing Card

underlying adenocarcinoma (eg, ovary, lung, pancreas).

Block Time Remaining: 00:01:10
TUTOR

5 | Feedback | Suspend | End Block

Settings

1
2
3
4
5
6
7
8
9
10
11
12
13
14
15
16
17
18
19
20

Item 19 of 20
Question Id: 700

Mark | Previous | Next | Full Screen | Tutorial | Lab Values | Notes | Calculator | Reverse Color | Text Zoom | Settings

A 24-year-old woman comes to the office at 12 weeks gestation for prenatal counseling. She is 120 cm (3 ft 11 in) tall with short upper and lower extremities but normal torso length. Physical examination is also significant for depression of the nasal bridge and a bulging forehead. Her husband is phenotypically normal and has no medical problems. The patient knows that there is a 50% chance of passing on her condition to the fetus. An abnormality involving which of the following cells is most likely responsible for this patient's features?

A. Chondrocytes
B. Hypothalamic neurosecretory cells
C. Osteoblasts
D. Osteoclasts
E. Pituitary somatotrophs

Submit

Block Time Remaining: 00:01:10
TUTOR

4 | Feedback | Suspend | End Block

A 24-year-old woman comes to the office at 12 weeks gestation for prenatal counseling. She is 120 cm (3 ft 11 in) tall with short upper and lower extremities but normal torso length. Physical examination is also significant for depression of the nasal bridge and a bulging forehead. Her husband is phenotypically normal and has no medical problems. The patient knows that there is a 50% chance of passing on her condition to the fetus. An abnormality involving which of the following cells is most likely responsible for this patient's features?

- ✓ A. Chondrocytes (86%)
- B. Hypothalamic neurosecretory cells (2%)
- C. Osteoblasts (3%)
- D. Osteoclasts (1%)
- E. Pituitary somatotrophs (6%)

Omitted
Correct answer
A

86%
Answered correctly

02 secs
Time Spent

03/07/2020
Last Updated

Explanation



Settings

1
2
3
4
5
6
7
8
9
10
11
12
13
14
15
16
17
18
19
20

Item 19 of 20
Question Id: 700

Mark | Previous | Next | Full Screen | Tutorial | Lab Values | Notes | Calculator | Reverse Color | Text Zoom | Settings

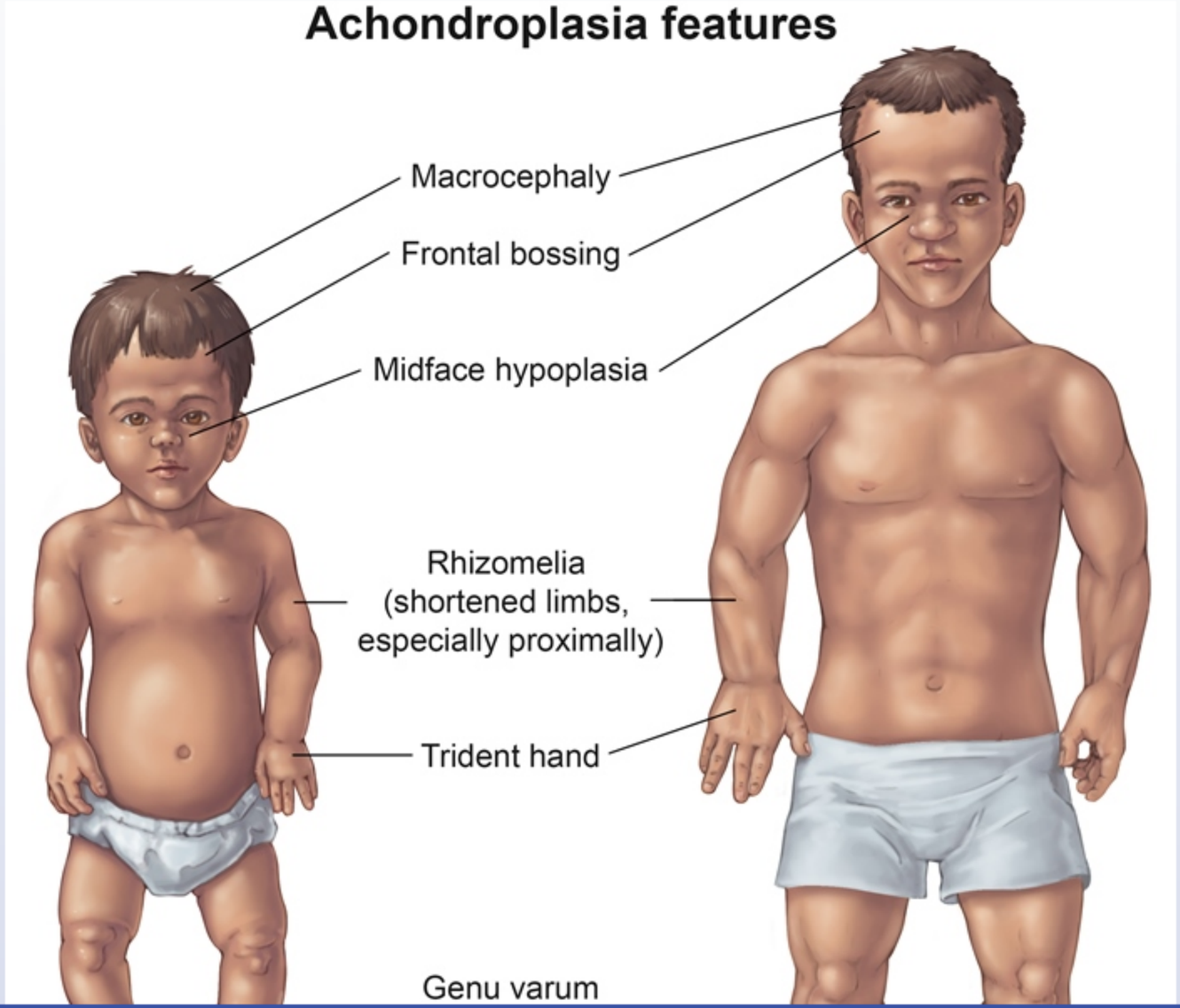

Block Time Remaining: 00:01:12
TUTOR

4 | Feedback | Suspend | End Block

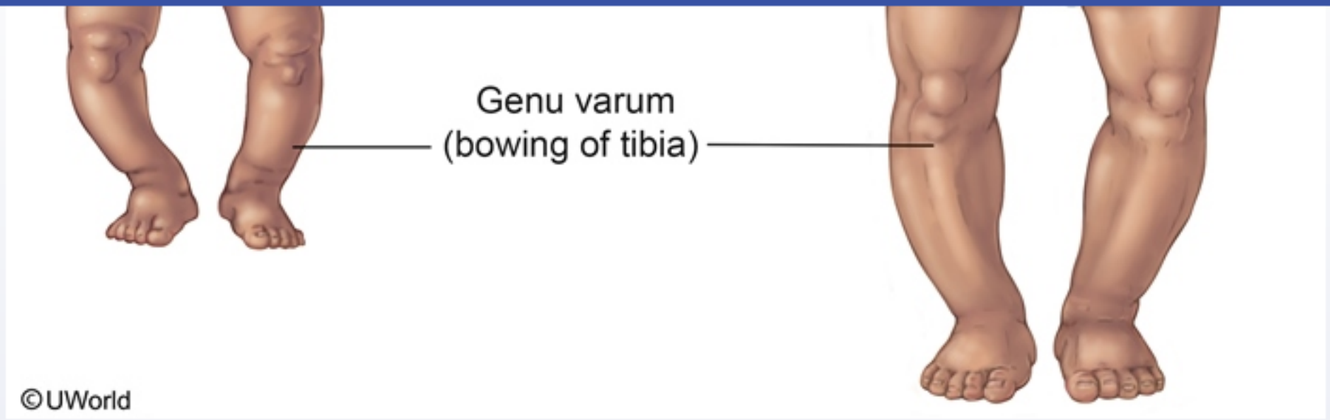

This patient's limb shortening with normal torso length, specific craniofacial features (frontal bossing, midface hypoplasia), and risk of passing the condition to her offspring (50%) are characteristic of **achondroplasia**. The condition is caused by an autosomal dominant point mutation in the fibroblast growth factor receptor 3 (*FGFR3*) gene; 90% are de novo (unaffected parents) and 10% are inherited. Because the mutation is **autosomal dominant**, the fetus of an affected and an unaffected parent has a 50% chance of inheriting the mutation.

Achondroplasia affects **endochondral ossification**, the process that makes **long bones** (eg, humerus, femur, phalanges) and portions of the skull and face. In endochondral bone formation, mesenchymal cells differentiate into chondrocytes that secrete cartilage matrix. These chondrocytes continue to proliferate through childhood, forming an elongating cartilage template that progressively becomes calcified and later invaded by osteoblasts, osteoclasts, and blood vessels originating from the periosteum. Deposition of osteoid matrix over the septa of calcified cartilage matrix forms woven bone, which then undergoes remodeling into compact bone.

FGFR3 is normally responsible for limiting chondrocyte proliferation during endochondral ossification. In achondroplasia, FGFR3 becomes constitutively activated, causing exaggerated **inhibition of chondrocyte proliferation** that results in the characteristic bone shortening and craniofacial abnormalities.

(Choices B and E) Hypothalamic neurosecretory cells produce growth hormone-releasing hormone and anterior pituitary somatotrophs produce growth hormone (GH). Hypothalamic or pituitary insults (eg, tumor, ischemia) can result in defective release of either hormone. GH deficiency can lead to proportional short stature (both long and flat bones affected) as opposed to the disproportionate short stature seen in achondroplasia (only long bones affected).

©UWorld

This patient's limb shortening with normal torso length, specific craniofacial features (frontal bossing, midface hypoplasia), and risk of passing the condition to her offspring (50%) are characteristic of **achondroplasia**. The condition is caused by an autosomal dominant point mutation in the fibroblast growth factor receptor 3 (*FGFR3*) gene; 90% are de novo (unaffected parents) and 10% are inherited. Because the mutation is **autosomal dominant**, the fetus of an affected and an unaffected parent has a 50% chance of inheriting the mutation.

Achondroplasia affects **endochondral ossification**, the process that makes **long bones** (eg, humerus, femur, phalanges) and portions of the skull and face. In endochondral bone formation, mesenchymal cells differentiate into chondrocytes that secrete cartilage matrix. These chondrocytes continue to proliferate through childhood, forming an elongating cartilage template that progressively becomes calcified and later invaded by osteoblasts, osteoclasts, and blood vessels originating from the periosteum. Deposition of osteoid matrix over the septa of calcified cartilage matrix forms woven bone, which then undergoes remodeling into compact bone.

FGFR3 is normally responsible for limiting chondrocyte proliferation during endochondral ossification. In achondroplasia, FGFR3 becomes constitutively activated, causing exaggerated **inhibition of chondrocyte proliferation** that results in the characteristic bone shortening and craniofacial abnormalities.

(Choices B and E) Hypothalamic neurosecretory cells produce growth hormone-releasing hormone and anterior pituitary somatotrophs produce growth hormone (GH). Hypothalamic or pituitary insults (eg, tumor, ischemia) can result in defective release of either hormone. GH deficiency can lead to proportional short stature (both long and flat bones affected) as opposed to the disproportionate short stature seen in achondroplasia (only long bones affected).

(Choice C) The flat bones (eg, most of the skull, pelvis) grow primarily via intramembranous (not endochondral) ossification. In intramembranous ossification, mesenchymal cells differentiate directly into osteoblasts and begin osteoid matrix secretion without the formation of cartilaginous bones. As a result, most flat bones remain unaffected in achondroplasia.

(Choice D) Osteoclasts are specialized macrophages that function to resorb bone. Paget disease, characterized by disordered bone mass, initially begins with excessive activity of abnormally large osteoclasts followed by osteoblastic activity and eventual sclerosis. Patients are usually elderly and can present with focal bone pain and pathologic fractures.

Educational objective:

constitutively activated, causing exaggerated **inhibition of chondrocyte proliferation** that results in the characteristic bone shortening and craniofacial abnormalities.

(Choices B and E) Hypothalamic neurosecretory cells produce growth hormone-releasing hormone and anterior pituitary somatotrophs produce growth hormone (GH). Hypothalamic or pituitary insults (eg, tumor, ischemia) can result in defective release of either hormone. GH deficiency can lead to proportional short stature (both long and flat bones affected) as opposed to the disproportionate short stature seen in achondroplasia (only long bones affected).

(Choice C) The flat bones (eg, most of the skull, pelvis) grow primarily via intramembranous (not endochondral) ossification. In intramembranous ossification, mesenchymal cells differentiate directly into osteoblasts and begin osteoid matrix secretion without the formation of cartilaginous bones. As a result, most flat bones remain unaffected in achondroplasia.

(Choice D) Osteoclasts are specialized macrophages that function to resorb bone. Paget disease, characterized by disordered bone mass, initially begins with excessive activity of abnormally large osteoclasts followed by osteoblastic activity and eventual sclerosis. Patients are usually elderly and can present with focal bone pain and pathologic fractures.

Educational objective:
Unlike the process of intramembranous ossification that forms flat bones, endochondral ossification proceeds along a cartilage template and is responsible for the formation of long bones. Achondroplasia is characterized by an exaggerated inhibition of chondrocyte proliferation in the growth plates of long bones and manifests with proximal limb shortening, midface hypoplasia, and macrocephaly.

References

- Pediatric aspects of skeletal dysplasia.
- Achondroplasia: from genotype to phenotype.

Pathophysiology	Rheumatology/Orthopedics & Sports	Achondroplasia
Subject	System	Topic

Copyright © UWorld. All rights reserved.

constitutively activated, causing exaggerated **inhibition of chondrocyte proliferation** that results in the characteristic bone shortening and

Exhibit Display

Paget disease of bone

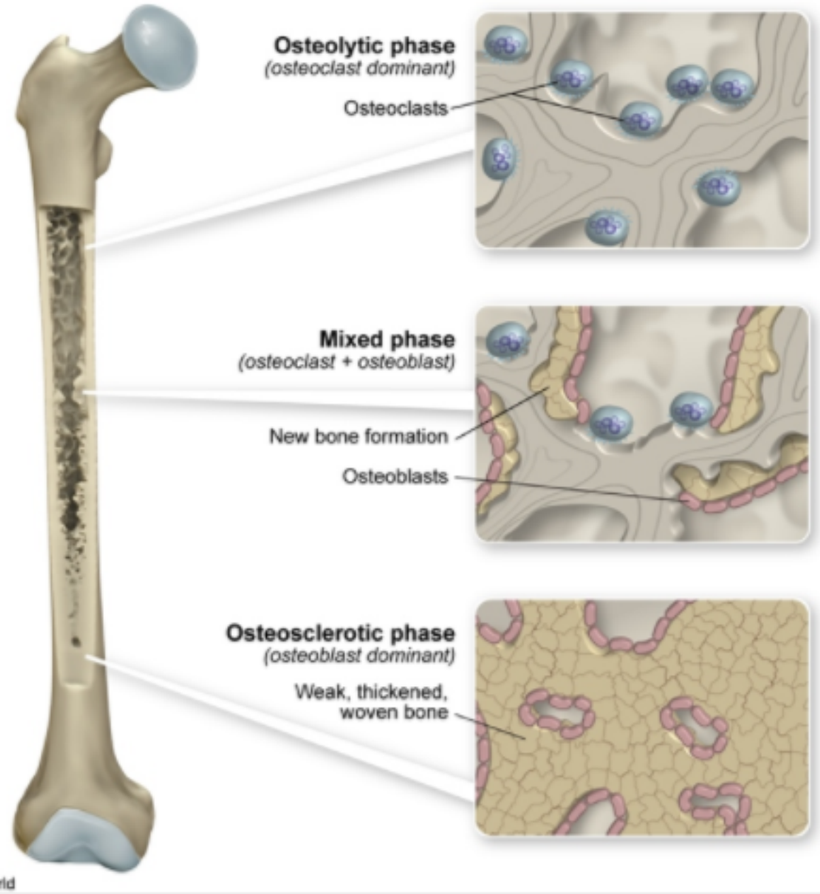

Zoom In | Zoom Out | Reset | Add To New Card | Existing Card

Settings

1
2
3
4
5
6
7
8
9
10
11
12
13
14
15
16
17
18
19
20

Item 20 of 20
Question Id: 19494

Mark | Previous | Next | Full Screen | Tutorial | Lab Values | Notes | Calculator | Reverse Color | Text Zoom | Settings

A 24-year-old man comes to the office due to severe pain in the posterior aspect of the right foot that interferes with walking. For the last several months, the patient has also experienced a dull backache and morning stiffness that is relieved by over-the-counter ibuprofen. Family history is insignificant, and he does not use tobacco, alcohol, or illicit drugs. Which of the following is the most probable location of the pathologic process responsible for this patient's foot pain?

A. Articular cartilage
B. Cortical bone
C. Periarticular bursae
D. Synovial membrane
E. Tendon insertion site

Submit

Block Time Remaining: 00:01:13
TUTOR

0 | Feedback | Suspend | End Block

A 24-year-old man comes to the office due to severe pain in the posterior aspect of the right foot that interferes with walking. For the last several months, the patient has also experienced a dull backache and morning stiffness that is relieved by over-the-counter ibuprofen. Family history is insignificant, and he does not use tobacco, alcohol, or illicit drugs. Which of the following is the most probable location of the pathologic process responsible for this patient's foot pain?

- A. Articular cartilage (12%)
- B. Cortical bone (7%)
- C. Periarticular bursae (3%)
- D. Synovial membrane (12%)
- ✓ E. Tendon insertion site (63%)

Omitted
Correct answer
E

63%
Answered correctly

02 secs
Time Spent

06/17/2020
Last Updated

Explanation

Enthesitis	
Location of inflammation	• Sites of mechanical stress • Insertion of tendons, ligaments, joint capsules
	• Achilles tendinitis (posterior heel pain)

Enthesitis	
Location of inflammation	• Sites of mechanical stress • Insertion of tendons, ligaments, joint capsules
Common presentations	• Achilles tendinitis (posterior heel pain) • Plantar fasciitis (plantar heel pain) • Dactylitis ("sausage digits")
Disease associations	• Ankylosing spondylitis • Psoriasis/psoriatic arthritis • Reactive arthritis

This patient has inflammatory back pain (ie, onset at age <40, chronic/insidious pain and stiffness that are better with activity and worse with rest), which is likely due to **ankylosing spondylitis** (AS).

In AS, the inflammatory process is thought to originate in the gut due to an altered intestinal biome and defects in the mucosal barrier; the resulting inflammatory response leads to upregulation of cytokines (primarily tumor necrosis factor-alpha and IL-17), with activation of innate immunity and migration of immune cells to the skeleton. The resulting **skeletal manifestations** are most prominent in areas of **mechanical stress**, primarily at the **insertions of tendons**, ligaments, and joint capsules (collectively, entheses) on bone.

Enthesitis is a relatively specific finding in AS and other forms of spondyloarthritis and is characterized by local pain, tenderness, and possible swelling. Common clinical syndromes include Achilles tendinitis, plantar fasciitis, and dactylitis ("sausage digits"). **Achilles tendinitis** affects the site of insertion of the Achilles tendon on the calcaneus and typically presents with severe pain at the **posterior aspect of the heel**.

(Choices A and D) Peripheral arthritis is common in AS. In these cases, the inflammatory process largely affects the articular cartilage and subchondral bone; synovial involvement is typically minor. However, the pain is typically felt within the ankle (eg, tibiotalar and subtalar arthritis) rather than at the posterior aspect of the foot.

(Choice B) Injury to the cortical bone of the calcaneus can occur acutely due to a high-velocity fall or crush injury or chronically due to a stress

This patient has inflammatory back pain (ie, onset at age <40, chronic/insidious pain and stiffness that are better with activity and worse with rest), which is likely due to **ankylosing spondylitis** (AS).

In AS, the inflammatory process is thought to originate in the gut due to an altered intestinal biome and defects in the mucosal barrier; the resulting inflammatory response leads to upregulation of cytokines (primarily tumor necrosis factor-alpha and IL-17), with activation of innate immunity and migration of immune cells to the skeleton. The resulting **skeletal manifestations** are most prominent in areas of **mechanical stress**, primarily at the **insertions of tendons**, ligaments, and joint capsules (collectively, entheses) on bone.

Enthesitis is a relatively specific finding in AS and other forms of spondyloarthritis and is characterized by local pain, tenderness, and possible swelling. Common clinical syndromes include Achilles tendinitis, plantar fasciitis, and dactylitis ("sausage digits"). **Achilles tendinitis** affects the site of insertion of the Achilles tendon on the calcaneus and typically presents with severe pain at the **posterior aspect of the heel**.

(Choices A and D) Peripheral arthritis is common in AS. In these cases, the inflammatory process largely affects the articular cartilage and subchondral bone; synovial involvement is typically minor. However, the pain is typically felt within the ankle (eg, tibiotalar and subtalar arthritis) rather than at the posterior aspect of the foot.

(Choice B) Injury to the cortical bone of the calcaneus can occur acutely due to a high-velocity fall or crush injury or chronically due to a stress fracture in athletes who run on hard surfaces. This patient's inflammatory back pain makes enthesitis a more likely cause of his heel pain.

(Choice C) Retrocalcaneal bursitis causes pain and swelling at the posterior heel near the insertion of the Achilles tendon. It is usually caused by overuse and often occurs in association with Achilles tendinopathy. However, it is significantly less common than enthesitis as a cause of posterior heel pain in AS.

Educational objective:
Enthesitis (inflammation at the bony insertions of tendons, ligaments, and joint capsules) is a prominent manifestation of spondyloarthritis (eg, ankylosing spondylitis). Common clinical syndromes include Achilles tendinitis, plantar fasciitis, and dactylitis. Achilles tendinitis affects the site of insertion of the Achilles tendon on the calcaneus and presents with severe pain at the posterior aspect of the foot.

References

- Review: enthesitis: new insights into pathogenesis, diagnostic modalities, and treatment.